

**Morphological and Histological Description of the Pecten Oculi in
the Sparrow Hawk (*Accipiter nisus*).
Jehan Mahmood Rajab**

**Morphological and Histological Description of the Pecten Oculi in the
Sparrow Hawk (*Accipiter nisus*)**

Jehan Mahmood Rajab

Department of Biology, University of Mustansiriya

Receiving Date: 2010/12/22 - **Accept Date:** 2011/3/17

Summary

In this study the pecten oculi of the sparrow hawk (*Accipiter nisus*), a diurnally active bird of prey, has been examined by light microscopy. In this species the pecten consists of (11- 12) highly vascularised pleats, held together apically by a heavily pigmented 'bridge' and projects freely into the vitreous body in the ventral part of the eye cup. Ascending and descending blood vessels of varying calibre, together with a profuse network of capillaries, essentially constitute the vascular framework of the pecten. A distinct distribution of melanosomes is discernible on the pecten, the concentration being highest at its apical end, moderate at the crest of the pleats and least at the basal and lateral margins. Overlying and within the vascular network, a close association between blood vessels and melanocytes is evident. It is conjectured that such an association may have evolved to augment the structural reinforcement of this nutritive organ in order to keep it firmly erectile within the gel-like vitreous. Such erectility may be an essential prerequisite for its optimal functioning, as well as in its overt use as a protective shield against the effects of ultraviolet light, which otherwise might lead to damage of the pectineal vessels .

Keywords: pecten oculi - sparrow hawk- morphology - histology

**Morphological and Histological Description of the Pecten Oculi in
the Sparrow Hawk (*Accipiter nisus*).
Jehan Mahmood Rajab**

Introduction

Birds have an anangiotic retina that receives nourishment from the pecten oculi and oxygenation from the choriocapillaris. The pecten is a nonsensory (Meyer,1977), highly pigmented structure of variable shape, extending from the optic nerve into the vitreous chamber (Pettigrew,et.al.1990). The pecten also provides an oxygen gradient to the retina (Wingstrand&Munk,1965),function in acid-base balance (Brach, 1975,1977),and maintains a constant intraocular temperature (Murphy&Dubielzing,1993) The shapes and number of pleats(folds)of the pecten vary among nocturnal and diurnal birds. Raptors, and most other birds, have the pleated type of pecten (Martin,1986), the other two types are conical in Kiwi and vaned in Ostrich (King&McLelland,1984) the purpose of these pleats is to increase the surface area of the pecten (Tucker,1975). Despite the variation of size and shape among species, in general, diurnal birds have a larger pecten with more folds than the nocturnal species (Jones,etal.2007). The activity of the birds may also play a factor in the variability of the pecten (Waldvogel,1990). Examples of these variations are the emu(*Dromaius novaehollandiae*), which has a primitive pleated pecten with (3-4)folds (Braekevelt,1998). the red-tailed hawk(*Buteo jamaicensis*), which has a very large pecten with (17-18)folds (Braekevelt,1991);the golden eagle, which has a (4-8)mm. in height pecten with (10)folds (Murphy&Dubielzig,1993);the spotted eagle owl, with a small(5-6)folds (Kiama,etal.2001) and the great horned owl(*Bubo virginianus*), with a smaller pecten having (7-8)folds (Braekevelt,1993). The amount of pecten pigmentation also varies among different species. Melanin is present in abundance at the apical and peripheral pecten. These pleomorphic melanocytes form incomplete sheaths along the vast plexus of capillaries. In doing so, they provide some structural support to the pecten and protect the blood vessels from ultraviolet light and oxygen radicals (Bennett&Cuthill,1994). The pecten oculi is draped by a covering membrane, which is thought to be continuous with the inner limiting membrane of the retina (Romanoff,1960;Bacha&Bacha,2000).

**Morphological and Histological Description of the Pecten Oculi in
the Sparrow Hawk (*Accipiter nisus*).
Jehan Mahmood Rajab**

Materials and Methods

A total of twelve eyes of adult and healthy Sparrow hawk birds were used for this work. These birds include three males and three females. The heads were removed from the body after slaughtering, the eyes were immediately excised and the pecten oculi carefully dissected out and immersed in the fixative (10% formalin solution) with two change . segments were washed up by tap water, then the segments processed as the following routine for a light microscopic examination:

1. Dehydration: Ethyl alcohol is the most commonly chemicals used for processes of dehydration in a series upgrading from over night of 60%, and 2 h. in 70%, 80%, 90%, 95% and 100%.
2. Clearing: Xylene is the most favorite for clearing tissues segments, when the tissue became translucent, the segments embedded in paraffin.
3. Embedding: The segments were embedded in the paraffin at melting point ranged from (56-58C°) of paraffin baths for 2 h.
4. Sectioning: Serially, the segments were sectioned in a plane at (5 μ m) by microtome.
5. Mounting: Each five sections were mounted on the clean glass slides.
6. Staining: The slides were stained respectively with (Harries Hematoxylin and Eosin stain) It is a routine stain in all histological work to investigate the general features of the tissue. and then covered with a cover slips. (Luna,1968).

Results

The pecten oculi of the sparrow hawk (Fig.1) is a thin, folded and heavily pigmented intraocular structure in a fan-like shape, widest at its base. The pecten situated over the optic disc and the contiguous stretch of the nerve fiber layer of the retina and projects freely into the vitreous body in the posteroventral surface of the eye. A light microscopy showed presence of (11-12) pleats (Fig.2) which varied in width from (0.39-0.40)mm. The pecteneal pleats were held together apically by a bridge ,a thickened mass of pecteneal tissue embedded in the posterior edge of the vitreous body, consists of polymorphic pigment cells (Melanocytes) with a few interspersed capillaries (Fig.3) .The pecten oculi is an extensive network of capillaries

**Morphological and Histological Description of the Pecten Oculi in
the Sparrow Hawk (*Accipiter nisus*).
Jehan Mahmood Rajab**

larger supply and drainage vessels (Fig.4), lined by flatted endothelial cells with a large plump nuclei and covered by a clear cytoplasm. Melanocytes fill the spaces between the capillaries and larger vessels, occurring individually or in small groups (Fig5). The melanocytes are most plentiful in the bridge region and peripherally in the pecten. The pecten oculi is draped by a covering membrane, which is thought to be continuous with the inner limiting membrane of the retina (Fig.6). Nerve fibers has not been demonstrated in the pecten.

Discussion

The sparrow hawk is a large diurnal bird of prey ,birds of prey are reputed to have keen vision (Shlaer,1976) and the pecten oculi has been considered to play a major role in the acquisition of the efficient visual mechanism (mann,1924). The location of the pecten in the sparrow hawk conform to the evident in other diurnal species of birds possessing a pleated type of pecten. It overlies the optic disc and the adjoining strip of the nerve fiber layer of the retina as shown in chick (Seaman&strom,1963; Bhattacharjee,1993). The present study demonstrates how the large conglomerate of pectineal blood vessels of varying caliber is effectively arranged and reinforced by an extensive contingent of melanosomes. Although investigators have attributed a supportive role to the pigmented intervascular tissue of the pecten (Meyer,1977; Braekevelt,1991). The numerous pleomorphic melanocytes interspersed between the capillaries are important in structural support of the pecten (Braekevelt,1994). The pecten plays an important role in the nourishment of the avascular avian retina and vitreous body (Dieterich,etal.1973;Rodriguez-Peralta,1968). The structural reinforcement of the pectineal blood vessels is important for maintaining the erectile function of the pecten and protecting the visual efficiency of the eye (Arey,1974). On the free apical half of the pectineal surface melanosomes form a thick investment over the anastomosing network of blood vessels, giving the latter a bloated appearance. The melanosomes at this part of the pecten appear to provide protection for the ensheathed blood vessels against exposure to incident ultraviolet light. High pigmentation of the pectineal bridge has been reported in the chick (Seaman&Strom,1963; Bhattacharjee,1993), pigons (Raviola&Raviola,1967) and vultures (Bawa&Yash Roy,1974). Bawa & Yash Roy (1974) suggested that this would

**Morphological and Histological Description of the Pecten Oculi in
the Sparrow Hawk (*Accipiter nisus*).
Jehan Mahmood Rajab**

favour light absorption and a consequent increase in pectineal temperature leading to increased physiological activity of this intraocular structure in the transport of nutrients to the retina (Wyganski, et.al.2007). However, it should be pointed out that the close association between the melanosomes and the capillaries, and the differential distribution of the melanosomes on the pectineal surface, as demonstrated in this study, cannot be fully explained by the provision of a rise of temperature in the pecten alone, although such a possibility cannot be excluded. The nutritive role of the pecten may possibly be mediated more efficiently along the basal half of the pecten and the lateral aspect of the pectineal pleats, where melanosomes are much fewer and the capillary network of blood vessels is partially exposed. These results suggest that the functional morphology of the pecten correlates with the life style of the bird and with functional need, and lends further support to the nutritive role of the pecten.

Conclusions

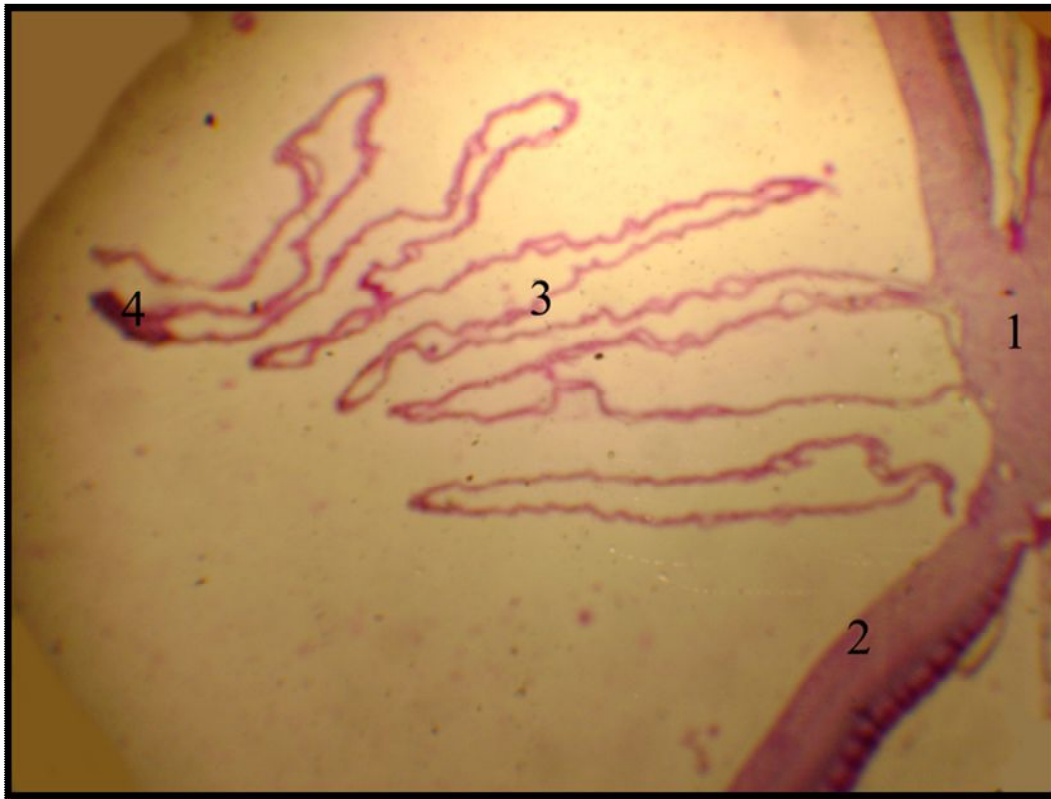
The pecten oculi is a thin, highly vascular, pleated membrane that protrudes into the cavity of the vitreous humor from the ventral surface of the eye. Its base is secured intermittently to the liner, optic disc. The apical surface is attached to a thickened mass of pectinal tissue called the bridge. The pecten oculi is characterized by an extensive network of capillaries lined by thick endothelial cells with plump nuclei. Polymorphic pigment cells fill the spaces between the capillaries and larger vessels. The pecten oculi is draped by a covering membrane, which is thought to be continuous with the inner limiting membrane of the retina .

Morphological and Histological Description of the Pecten Oculi in
the Sparrow Hawk (*Accipiter nisus*).
Jehan Mahmood Rajab



(Fig.1) sparrow hawk (*Accipiter nisus*).

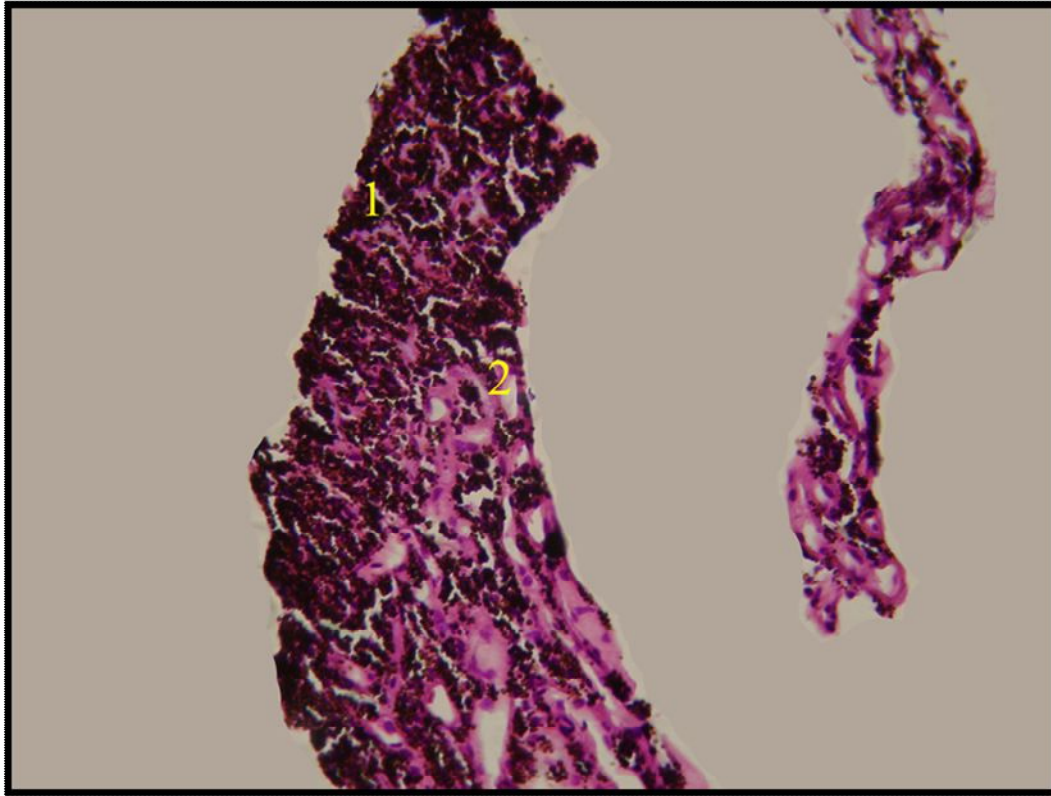
Morphological and Histological Description of the Pecten Oculi in
the Sparrow Hawk (*Accipiter nisus*).
Jehan Mahmood Rajab



(Fig.2) Section through the pecten oculi showing: a thin, folded and heavily pigmented membrane that projects into the vitreous humor from the posteroventral surface of the eye, presence of (11-12) pleats. 1- Optic nerve ; 2- Retina ; 3- Pecten oculi pleat ; 4- Bridge .

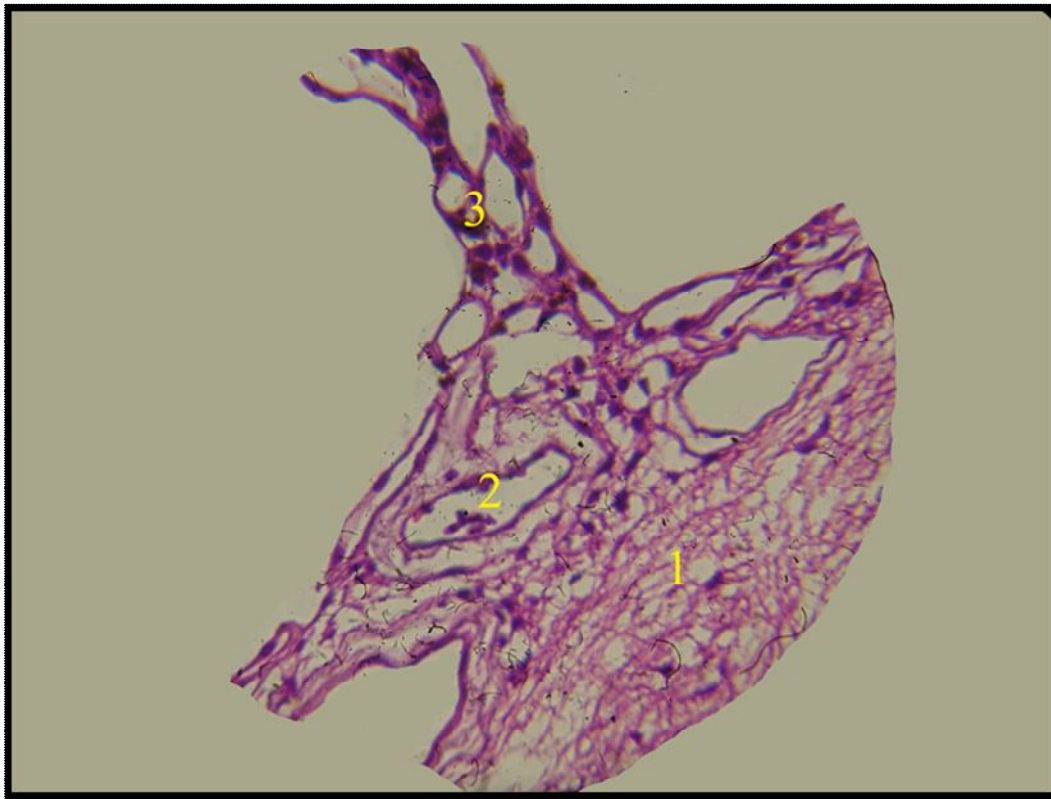
(H&E) stain (10x)

Morphological and Histological Description of the Pecten Oculi in
the Sparrow Hawk (*Accipiter nisus*).
Jehan Mahmood Rajab



(Fig.3) Section through the pecten oculi bridge showing: thickened and highly pigmented mass of pectinal tissue is located along the free edge of the pecten. 1-Melanocytes, 2-Capillaries (H&E) stain (25x)

Morphological and Histological Description of the Pecten Oculi in
the Sparrow Hawk (*Accipiter nisus*).
Jehan Mahmood Rajab

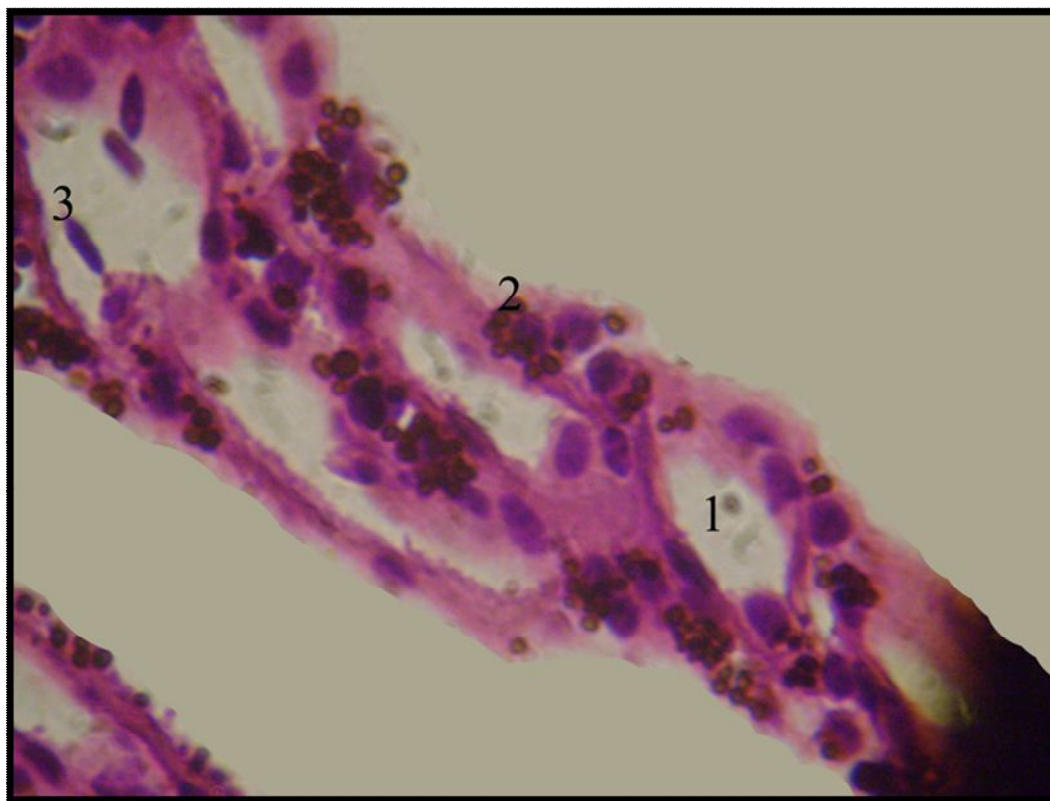


(Fig.4) Section through the pecten oculi base showing: a complex vascular network of both large and small blood vessels.

1-Optic nerve ; 2- Large blood vessel ; 3- Small blood vessel

(H&E) stain (25x)

Morphological and Histological Description of the Pecten Oculi in
the Sparrow Hawk (*Accipiter nisus*).
Jehan Mahmood Rajab

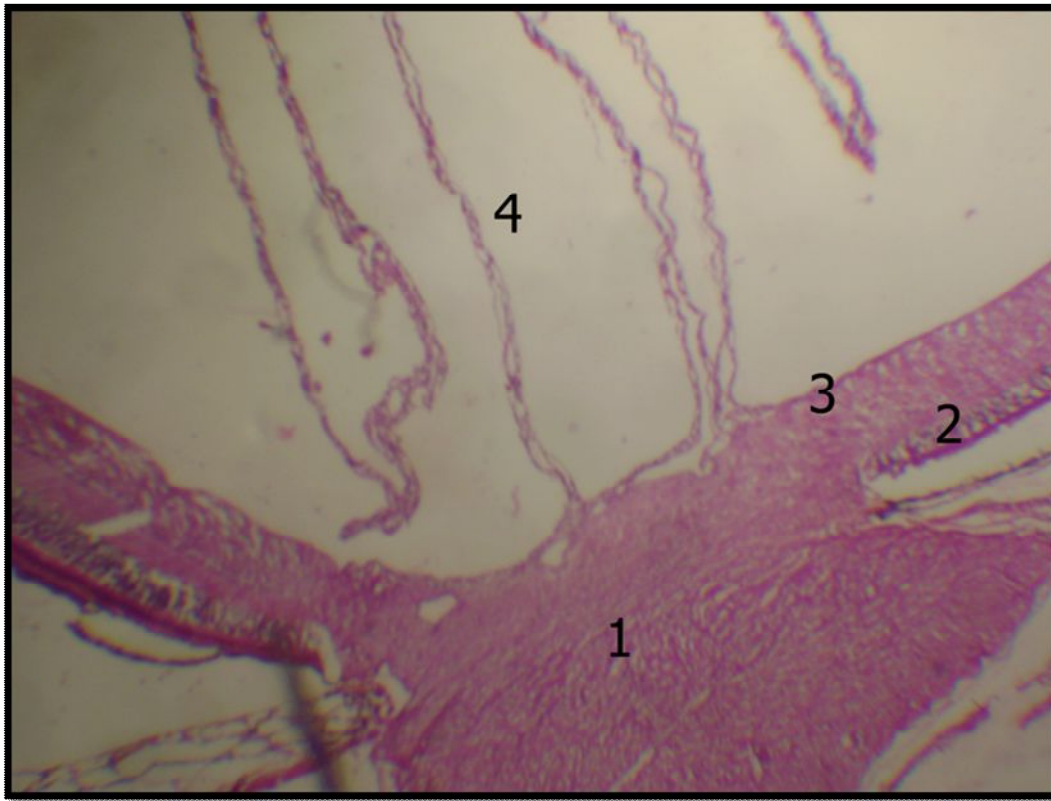

(Fig.5) High power photomicrograph of the pecten oculi pleat showing Numerous and polymorphic melanocytes are interspersed through this highly vascularized and nutritive membrane. The large capillaries are lined by thick endothelial cells with plump nuclei .

1- Blood vessel ; 2- Melanocytes ; 3- R.B.C.

(H&E) stain (100x)

Morphological and Histological Description of the Pecten Oculi in
the Sparrow Hawk (*Accipiter nisus*).
Jehan Mahmood Rajab



(Fig.6) pecten oculi is draped by a covering membrane, which is continuous with the inner limiting membrane of the retina.

1- Optic nerve ; 2- Retina ; 3- Inner limiting membrane ; 4- pecten oculi pleat

(H&E) stain (10x)

Morphological and Histological Description of the Pecten Oculi in
the Sparrow Hawk (*Accipiter nisus*).
Jehan Mahmood Rajab

References

- Arey, L.B. (1974) Human histology. A Text book in Outline Form. Fourth ed. W.B. Saunders Company Philadelphia .
- Bacha, W. J. and Bacha, L. M. (2000) Color Atlas of Veterinary Histology. Second edition. Lippincott Williams & Wilkins. Pp :249.
- Bawa, S. R. and Yash Roy, R. C. (1974) Structure and function of vulture pecten .Acta Anatomica Vol. 89, Pp:473 – 480 .
- Bennet, A. T. and Cuthill, I. C. (1994) Ultraviolet vision in birds, what is its function . Vision Res. Vol. 34 , Pp: 1471 – 1478 .
- Bhattacharjee, J. (1993) A presumably astroglial cell in the retinopectineal junction in (*Gallus domesticus*) demonstrated by nonspecific esterase staining. European Journal of Morphology vol.31, Pp.169-173.
- Brach, V. (1975) The effect of intraocular ablation of the pecten oculi of the chicken. Invest Ophthalmol .Vol. 14.Pp:166–168.
- Brach, V. (1977) The functional significance of the avian pecten. Condor, Vol.79, Pp.:321-327.
- Braekevelt, C .R . (1991) Fine structure of the pecten oculi of the red-tailed hawk (*Buteo jamaicensis*). Anat. Histol. Embryol . Vol. 20 , Pp: 354 - 362.
- Braekevelt, C.R. (1993) Fine structure of the pecten oculi in the great horned owl (*Bubo virginianus*). Histol. Histopathol. vol.8, Pp.9-15.
- Braekevelt, C.R. (1994) Fine structure of the pecten oculi in the American crow (*Corvus brachyrhynchos*) .Ant.Hist.Embr. Vol.23, Iss.4, Pp357-366.
- Braekevelt, C.R. (1998) Fine structure of the pecten oculi of the emu (*Dromaius novaehollandiae*). Tissue and Cell. Pp.157-165.

**Morphological and Histological Description of the Pecten Oculi in
the Sparrow Hawk (*Accipiter nisus*).
Jehan Mahmood Rajab**

- Dieterich,C.E.;Dieterich,H.J.;Spycher,M.A. and Dfautsch,M.(1973) Fine structural observations of the pecten oculi capillaries of the chicken.Vol.146, No.4, Pp.473-489.
- Jones , M . P . ; Pierce , K . E . and Ward , D . (2007) Avian vision: areview of form and function with special consideration to birds of prey. Journal of exotic pet medicine, Vol. 16. No. 2 ,Pp: 69-87.
- Kiama,S.G.;Maina,J.N.;Bhattacharjee,J.and Weyrauch,D. (2001) Functional morphology of the pecten oculi in the nocturnal spotted eagle owl(*Bubo bubo africanus*),and the diurnal black kite (*Milvus migrans*) and domestic fowl (*Gallus gallus var. domesticus*): a comparative study. Journal of zoology, Vol.254,Issue 04,Pp.521-528.
- King , A .S . and McLelland , J . (1984) Special sense organs, in Birds: Their Structure and Function . Arrowsmith J. W. press, 2nd . Ed ., Bristol, Great Britain. Pp: 284- 314.
- Luna , L . G . (1968) Manual of histologic staining method of Armed Forces institute of pathology . Third ed .Mc Graw – Hill book Company . New York.
- Mann, I. C. (1924) The function of the pecten. British Journal of Ophthalmol .Vol. 8 ,Pp: 209–226.
- Martin , G . R . (1986) . Short comings of an eagle’s eye. Nature Vol. 319, Pp: 357.
- Meyer . D. (1977) The avian eye and its adaptations, in Crescitelli F (ed): Handbook of Sensory Physiology. Berlin , Springer-Verlag. Pp: 564-566.
- Murphy , C .J . and Dubielzig . R .R .(1993) The gross and microscopic structure of the golden eagle (*Aquila chrysaetos*) eye. Prog. Vet. Comp. Ophthalmol.Vol. 3 ,Pp :74-79.
- Pettigrew, J.D.; Wallman, J. and Wildsoet, C.F.(1990) Saccadic oscillations facilitate ocular perfusion from the avian pecten. Nature, Vol.343,Pp:362-363.
- Raviola, E. and Raviola, G. (1967) A light and Electron microscopic study of the Pecten of the pigeon eye. Americal Journal of Anatomy .Vol. 120, Pp: 427-461.
- Rodriguez-Peralta, L.A. (1968) Hematic and flui barriers of the retina and vitreous body. Journal of Comparative Neurology. Vol. 132 , Pp: 109-124.

**Morphological and Histological Description of the Pecten Oculi in
the Sparrow Hawk (*Accipiter nisus*).
Jehan Mahmood Rajab**

- Romanoff, A.L.(1960).** The Avian Embryo. Structural and Functional Development. MacMillan Co. New York, NY.
- Seaman,A.R. and Storm, H. (1963)** Acorrelated light and electron microscope study of the pecten oculi of the domestic fowl (*Gallus domesticus*) . Exp . Eye . Res. Vol. 2, Pp: 163-172.
- Shlaer,R.(1976)** An eagle's eye:quality of the retinal image. Science, Vol. 176, Pp:920-922.
- Tucker, R. (1975).** The surface of the pecten oculi in the pigeon. Cell Tissue Res. Vol.157, Pp: 457- 465.
- Waldvogel, J.A. (1990)** The bird's eye view. American Scientist. . Clemson, SC. 178 .Pp: 342-353.
- Wingstrand,K.G. and Munk,o.(1965)** The pecten oculi of the pigeon with particular regard to it's function. Biology, Vol. 14, Pp.:1- 64.
- Wynanski-Jaffe, T. ; Murphy,C. J. ; Smith,C. ; Kubai, M. P. ; Christopherson,C.R. ;Ethier and Levin, A.V. (2007)** Protective ocular mechanisms in woodpeckers . Nature Publishing Group .Eye . Vol. 21, Pp: 83 - 89.