

## Effect of Carrot Extract on Biochemical and Histopathological Profiles in local Male Rabbits Treated with Food Dye Tartrazine

Mohammed Abed Mahmood

Department of Pathology, Faculty of Veterinary Medicine, University of Diyala,  
Iraq

Correspondence E-mail: [mohammedvet87@gmail.com](mailto:mohammedvet87@gmail.com)

### Abstract

Carrots are an important food and are rich in carotenoids and vitamin A, which is considered one of the most important antioxidants, it resists the formation of free radicals in various organs and tissues of the body. The purpose of the now study is to determine the effect of food dye (tartrazine) on biochemical parameters and histopathological changes in the liver and to know the effect of carrots extract on previous mentioned parameters. 18 local male rabbits were divided into three groups: each group included six rabbits. The first group (control group) was given distilled water daily for 30 days. The 2nd group was given the colored food dye tartrazine at a dose 1g/ kg of body weight for 30 days. The 3rd group given carrot extract orally, after three hours, the tartrazine dye was also given for 30 days. The biochemical result revealed elevated of liver enzyme (AST, ALP and ALT) in tartrazine group while the value of these enzymes in third group resemble to control group. Histopathological changes: In control group, the liver showed normal tissue architectures. Second tartrazine group showed liver with inflammatory cells and congestion as well as multiple vacuoles and necrosis. Third group (carrot & tartrazine group) showed very slightly hepatocytic degeneration and absent of other changes like necrosis and yellow pigments which present in second group. The biochemical and histopathological results showed dangerous effect of tartrazine and in same time the beneficials effect of carrot as antioxidant in diminish the toxic liver injury by tartrazine.

**Keyword:** Tartrazine, Carrot, Antioxidant, Liver, Hepatocytes



This is an open access article licensed under a [Creative Commons Attribution- NonCommercial 4.0 International License](https://creativecommons.org/licenses/by-nc/4.0/).

## Introduction

Many peoples used the food dye without any information about safety of it. Tartrazine (E102) is synthetic colorant play important role in food industries as food dye additive organic compound. This material allowed some people to be happy and comfortable when eating it due to its attractive colors, while at the same time getting rid of the daily shopping routine. The Iraqi food additives available in the market have widely used food colorings, and one of these colorings is tartrazine. Food colorings are defined as substances that add a specific color to food, cosmetics, and medicines, most of which are of natural origin. Food colorings can remain for long periods of time, extending to many years (1). Food coloring makes people choose a type of food based on their desire for certain colors, regardless of the type of food (2). Food colors give rise to a feeling of love to know the extent to which people want to determine the taste, flavor, and color of food. Many research experiments have proven that matching the taste and color of a specific person can achieve great economic results by increasing the results for food color, and vice versa, when the consumer does not want food color, it will lead to results. Sometimes we lose

money on the industrial product and mayo, due to the presence of individual differences between people in terms of their desire for a certain food color over another (3). Tartrazine is food dye, water soluble, lemon flavor and yellow in color. Soft drink, food, candy, cotton and some chips contain tartrazine (4), also found in drink, cake, jam, some rice, candy, soup, hair shampoos (5), and medical products such as zinc, some capsules and some other drugs (6). Tartrazine is synthetic food dye, metabolism of it may be lead to generation of free radicles and causes cellular injury (7). Some sings recorded by tartrazine as depression, weakness, fever and disturbance of sleep (8). Tartrazine causes interaction with some drug as Ventolin and aspirin (9). Carrot is favored food source of the rabbits which consider antioxidant because of rich in vitamin A and carotenoids (10) Because of still use of tartrazine as food additive, this study will investigate the biochemical and histopathological changes of tartrazine in rabbits and effect of carrot extract on it.

## Material and methods

**Animals:** Eighteen local male rabbits 2.5 kg, 3-month years old were used in

current study, then housed in room (temperature 23°C), (12 light: 12 dark) with suitable drink and food along experimental periods. Animal divided in to three groups: each group consist of six rabbits. Control group received distal water orally and second group received tartrazine by oral rout for 30 days. Third group received carrot extract, followed by three hours given tartrazine orally for 30 days.

**Tartrazine:** or E102, it is yellow colorant dye, take from Iraqi company of food industries. The dose of tartrazine in kg of body weight /rabbits Ld50 of 1 g dissolved in distal water according to study in 1964 and in 2009 (11),(12).

**Biochemical procedures:** Take blood sample from ear artery of each rabbit, then in clean tube, Blood serum for identify the ALT,AST,ALP(13).

**Histopathological procedures:** Rabbits under general anesthesia by ketamine, after that, take sample from liver fixed in

10% natural formalin, serious concentration of ethanol, two steps of xylol, waxes of paraffin, section by microtome and stain with hematoxylin and eosin stain, al histopathological procedures according to (14).

**Statistical study:** Anova used for comparison between control group and second tartrazine group, significant difference  $P < 0.05$  using mean slandered error.

#### **Results:**

**Biochemical parameters** include AST, ALP and ALT of liver enzyme in control group and carrot group represent in Table 1. AST, ALP and ALT in second tartrazine group showed significant increase  $P < 0.05$  than control group and third carrot tartrazine group. Also, there is decrease in this previous liver enzyme than tartrazine treated group and there are no significant differences between control group and carrot & tartrazine third group (Table 1).

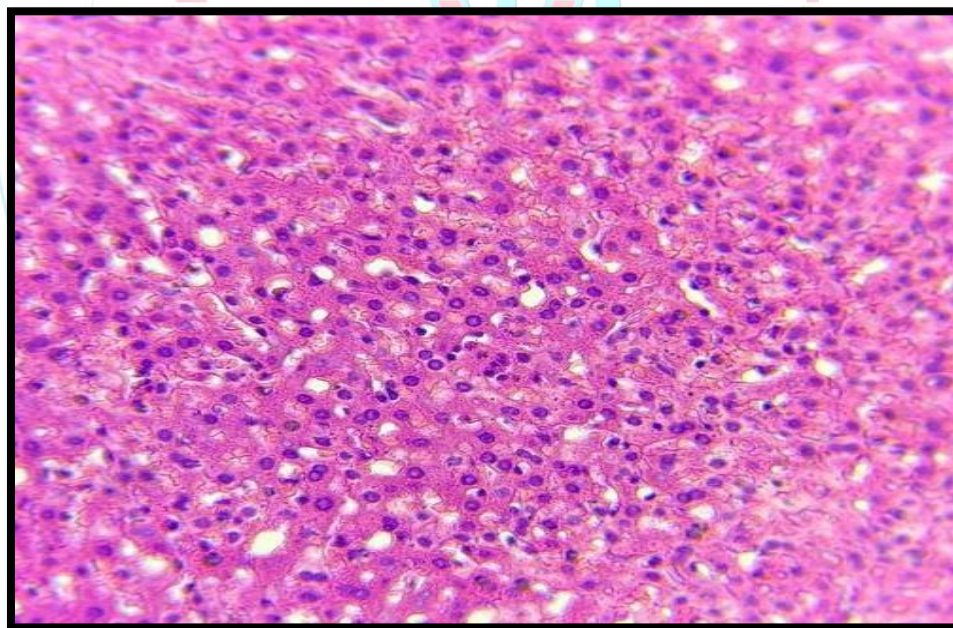


**Table 1** showed level of study liver enzymes on each group.

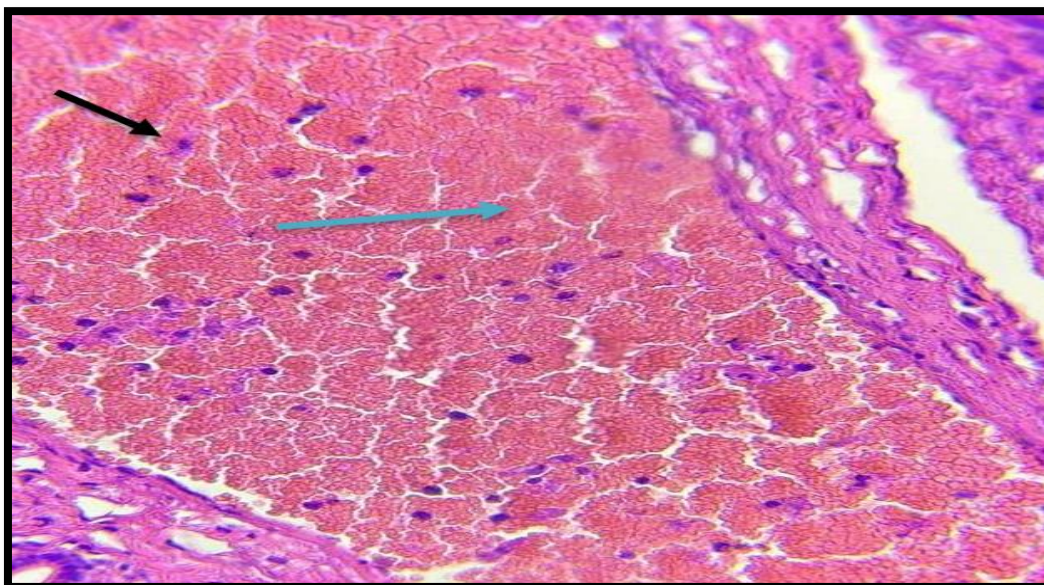
Liver enzyme	Control group (Mean ± SE)	Tartrazine group (Mean ± SE)	Carrot group and tartrazine (Mean ± SE)
AST (U/L)	0.40 ± 0.05	0.65 ± 0.25	0.45 ± 0.10
ALP(IU/L)	48.3± 0.20	75.5± 0.05	50± 0.05
ALT(IU/L)	122±1.5	155±7.5	135±0.5

- The significant difference \* control group to tartrazine group at  $P < 0.05$ .

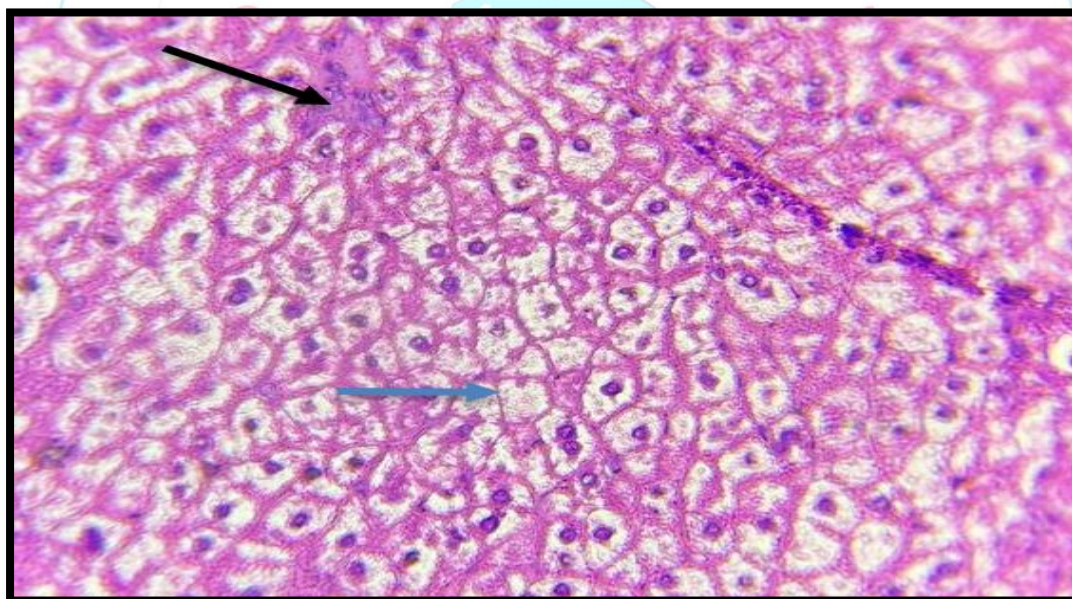
**Histopathological changes:** In control group, the liver showed normal tissue architectures (figure 1). Second tartrazine group showed liver with inflammatory cells and congestion (figure 2), as well as multiple vacuoles and necrosis (figure 3). Third group (carrot & tartrazine group) showed very slightly hepatocytic degeneration and absent of other changes like necrosis and yellow pigments which present in second group (figure 4).



**Figure 1:** normal tissue architectures of liver of control group at 40X (H&E stain).

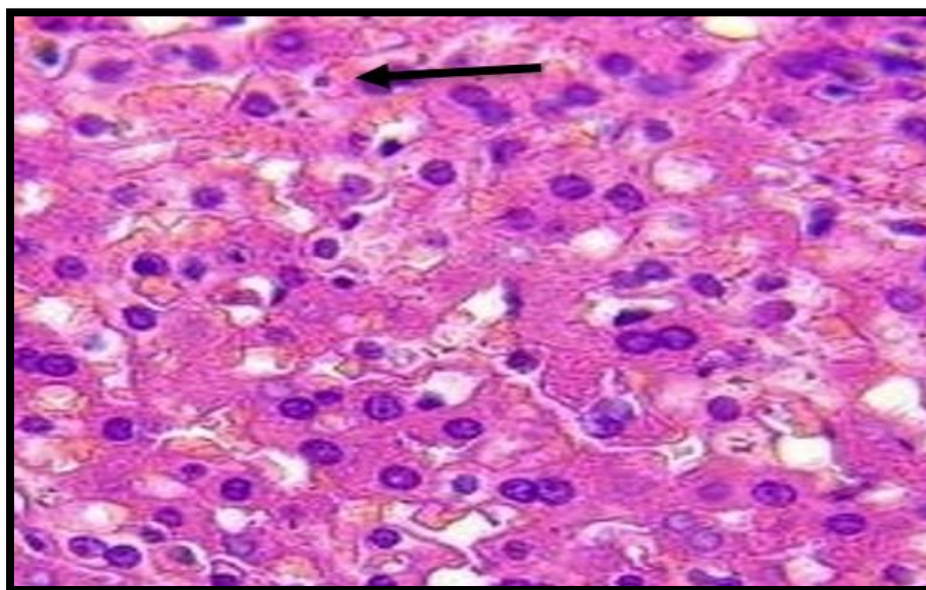


*Figure 2: second tartrazine treated group showed liver with inflammatory cells (black arrow) and congestion of it (blue arrow) at 40X, (H&E stain).*



*Figure 3: second tartrazine treated group showed liver with multiple vacuoles (blue arrow) and necrosis (black arrow) at 40X (H&E stain).*





**Figure 4:** Third carrot & tartrazine group showed slightly liver hepatocytic degeneration (black arrow) at 40X, (H&E stain).

#### Discussion:

Current study reveal significant increase ( $0.65 \pm 0.25$ ) of AST at  $P < 0.05$  in second tartrazine group compare with control group, this agreement with (15), significant increase ( $75.5 \pm 0.05$ ) of ALP at  $P < 0.05$  comparison with control group (16) and significant increase ( $155 \pm 7.5$ ) of ALT at  $P < 0.05$  comparison with 1<sup>st</sup> control group which agreement with (17), The explanation for the reason for this increase is due to the effectiveness of tartrazine dye, which caused destruction and necrosis in the liver, which led to an increase in the secretion of these enzymes (18). Third group reveal decrease of the liver enzyme which previously increased in second tartrazine group and this may be belong to antioxidant activity of carrot which

contain Vitamin A that prevent production the free radicles and reactive oxygen species which caused liver injury by tartrazine (19). Carrot lead to decrease elevation of liver enzyme result in return to normal, this may be prevent production of these enzyme duo to stabilization of cell membrane and protect the hepatocytes from free radicles and start hepatic regeneration (20). The histopathology result of third group is indicator of protective role of carrot on the liver. No changes of histopathology in control group, microscopical changes present in second tartrazine group include inflammatory cells and congestion of liver similar to other study which reported hepatic changes duo to tartrazine (21), (22). Carrot contain vitamin A which act as antioxidant vitamin (23). Carrots are rich in

benefits and are considered antioxidants. They are rich in beta-carotene, which is a plant pigment belonging to the group of carotenoids that converts to vitamin A, which is important for good nutrition, maintaining weight, and the health of the body because it is an important antioxidant. Carrots are also rich in alpha-carotenoids, which convert to vitamin A.(23). In current study, the carrot can improve the biochemical profile results in rabbits and this agreement with (24), because antioxidant activity and consider important source of vitamin A, beta carotin, vitamin B,C (25). In this study the carrot reduce the liver injury and this agreement with (26) which mention the carrot lead to reduce free radicles in the liver.

**Conclusion:** Tartrazine or E102 is food adaptive dye and used in food industries led to hepatotoxic injury. Used of carrot causes decrease effect of tartrazine in rabbits which increased liver enzyme studied in this study and also supported by histological study on the liver.

### References

1. Mahmood RA, Mohammed SS. Kinetic and thermodynamic study of adsorption of an industrial food dye using Iraqi clay. *J Popul Ther Clin Pharmacol.* 2023;30(5):279–87.
2. Magoulas C. How color affects food choices. 2009;
3. Spence C. On the psychological impact of food colour. *Flavour.* 2015;4(1):1–16.
4. Ds J. N., A.(2022). Evaluation of azo dye Tartrazine in the synthetic food items common in South India. *Acad Lett.* :2.
5. Marmion D. Colorants for Foods, Drugs, and Cosmetics. *Kirk-Othmer Chem Technol Cosmet.* 2013;501–47.
6. Amin KA, Al-Shehri FS. Toxicological and safety assessment of tartrazine as a synthetic food additive on health biomarkers: A review. *African J Biotechnol.* 2018;17(6):139–49.
7. Eman GM, Ibrahim MA, Hassan AMH, Ebtehal MF. Quercetin nanoparticles repressed liver and brain toxicities induced by tartrazine in rats. *J Drug Deliv Ther.* 2018;8(5):230–40.
8. El-Sakhawy MA, Mohamed DW, Ahmed YH. Histological and immunohistochemical evaluation of the effect of tartrazine on the cerebellum, submandibular glands, and kidneys of adult male albino rats. *Environ Sci Pollut Res.* 2019;26:9574–84.
9. Teuber SS. Foods, Additives, and Nonsteroidal Anti-Inflammatory Drugs in Asthma. *Bronchial Asthma Princ Diagnosis Treat.* 2001;315–41.
10. Ewuola EO, Odefemi TR. Growth response, organ morphometry, sperm production and reserve in rabbit bucks administered carrot fruit extracts. *Niger J Anim Prod.*

- 2019;46(1):30–6.
11. Jones R, Ryan AJ, Wright SE. The metabolism and excretion of tartrazine in the rat, rabbit and man. *Food Cosmet Toxicol*. 1964;2:447–52.
  12. Food EP on FA and NSA to. Scientific Opinion on the re-evaluation Tartrazine (E 102). *EFSA J*. 2009;7(11):1331.
  13. Jayaraman J, Jayaraman J. Laboratory manual in biochemistry. Wiley Eastern Delhi, India;; 1981.
  14. Bancroft JD, Gamble M. Theory and practice of histological techniques. Elsevier health sciences; 2008.
  15. Al-Shaikh TM. Ameliorating Effect of Vitamin E on Liver Damage Caused by Administering Tartrazine in Male Mice. *Asian J Pharm Res Heal Care*. 2021;13(1):61–9.
  16. Abd El Naby BE, Shalaby RA, Fouda FM, Ebiya RA. EVALUATION OF BIOCHEMICAL EFFECTS OF TARTRAZINE AND CURCUMIN IN MALE ALBINO RATS. 2022;
  17. Somacal S, Quatrin A, Ruviaro AR, Conte L, da Silva DT, Roehrs M, et al. Norbixin<sup>23</sup> a natural dye that improves serum lipid profile in rabbits and prevents LDL oxidation. *Food Res Int*. 2022;159:111522.
  18. Ameer FZ, Mehedi N, Soler Rivas C, Gonzalez A, Kheroua O, Saidi D. Effect of tartrazine on digestive enzymatic activities: in vivo and in vitro studies. *Toxicol Res*. 2020;36:159–66.
  - Okafor SN, Obonga W, Ezeokonkwo MA, Nurudeen J, Orovwigho U, Ahiabuike J. Assessment of the health implications of synthetic and natural food Colourants–A critical review. *Pharm Biosci J*. 2016;1–11.
  - Chatatikun M, Chiabchalard A. Phytochemical screening and free radical scavenging activities of orange baby carrot and carrot (*Daucus carota* Linn.) root crude extracts. *J Chem Pharm Res*. 2013;5(4):97–102.
  21. Yahya LT, Hassan SL, Hasan HF. TOXICOPATHOLOGICAL CHANGES IN INTERNAL ORGANS OF ALBINO MICE AFTER TREATMENT WITH TARTRAZINE. *Biochem Cell Arch*. 2021;21(1).
  - Arefin S, Hossain MS, Neshe SA, Rashid MMO, Amin MT, Hussain MS. Tartrazine induced changes in physiological and biochemical parameters in Swiss albino mice, *Mus musculus*. *Marmara Pharm J*. 2017;21(3):564–9.
  - Clagett-Dame M, Knutson D. Vitamin A in reproduction and development. *Nutrients*. 2011;3(4):385–428.
  24. Ewuola EO, Opesemowo AO, Adisa OH. Growth, haematology and serum biochemical responses of rabbit bucks administered carrot



- (daucus carota) seed meal. Niger J Anim Sci. 2023;25(3):27–37.
25. Bystrická J, Kavalcová P, Musilová J, Vollmannová A, Tomáš T, Lenková M. Carrot (*Daucus carota* L. ssp. *sativus* (Hoffm.) Arcang.) as source of antioxidants. Acta Agric Slov. 2015;105(2):303–11.
26. Hammerich L, Tacke F. Eat more carrots? Dampening cell death in ethanol-induced liver fibrosis by  $\beta$ -carotene. Hepatobiliary Surg Nutr. 2013;2(5):248.

