

## Subclinical Endometritis: Fungal identification and treatment of conception failure in Cows

Mohammad Yousif Mahmood\*Yaseen Mahmood Rasheed\* , Salman Hammadi Ghareeb\*, Noor Their Talib\* \*

\*Department of Veterinary Surgery & Obstetrics.

\*\* Department of Microbiology/College of Veterinary Medicine-Diyala University

*E.mail: moyo131166@gmail.com*

### Abstract

Endometritis, which is one of the most common diseases in dairy cows postpartum, causes severe economic losses, including increased open days, calving intervals, and numbers of services to achieve conception. The objective of this study was to define the optimal clinical and microbial diagnostic criteria for Subclinical endometritis (SCE) in dairy cows and evaluation commonly used, commercially available, treatments for Subclinical endometritis (SCE). This study was carried out in the College of Veterinary Medicine - Diyala University. Sixteen Multiparous cows (4-7 years old) that diagnosed as cases of Subclinical endometritis using microbial identification. the results of the highest isolation are *Aspergillus niger* , *Aspergillus fumigatus* , *Rhizopus* spp. and *Alternaria* spp., which were (8/16,50%;6/16,37.5%;5/16,31.3% and 3/16,19%) respectively. The animals were divided into two equal groups ,first group was treated with 2gm of oxytetracycline 10% as intrauterine (IU) therapy, while the second group treated with lugol's iodine solution(0.5%) intrauterine (IU), the results showed that the number of cows responded were (4/8, 50% and 7/8, 87.5%), respectively. The result as far as the treatment to conception were recorded in 2<sup>nd</sup> group in comparison to the 1<sup>st</sup> group. From these observed , we concluded that lugol's iodine solution gives the best results in the treatment of endometritis in cows.

**Keywords:** Endometritis, Oxytetracycline, Lugol's iodine, Cows



This is an open access article licensed under a [Creative Commons Attribution- Non-Commercial 4.0 International License](https://creativecommons.org/licenses/by-nc/4.0/).

## Introduction:

Endometritis is defined as an inflammation of the endometrium. It is characterized by the presence of a mucopurulent vaginal discharge, 21 days or more after calving and associated with delayed uterine involution (1) Mycotic endometritis is becoming a matter of concern in repeat breeder cows now a days. The increase in the prevalence of mycotic endometritis has been attributed to several reasons including regular and in discriminates use of I/U antibiotics , postpartum uterine contamination and compromises in hygenic during AI procedures (2). Fungus is well capable of producing reproductive failures in bovines. As fungus is an opportunistic pathogen, there are more chances for fungus to cause infection in the uterus when certain predisposing factors like prolonged intra-uterine antibiotic therapy, persistent endometritis, presence of necrotic foci, immunosuppression, and pneumovagina are available(3).

The incidence of subclinical endometritis in beef cows is unknown, and there is a lack of information on it. Therefore, the first objective of this study was to define the optimal clinical and microbial diagnostic criteria for endometritis in dairy cows based on their

effect on subsequent reproductive performance. The second objective was to trials treated them with different intra uterine (IU)

## Materials and Methods:

Sixteen regular cyclic multiparous cows (4-7 years old) ,were presented to the Veterinary Clinical Service in College of Veterinary Medicine- Diyala University; the study was conducted during the period from October 2020-March 2021.

Gynecological examination of these cows revealed no palpable abnormalities of the reproductive organ. The entire reproductive tract was examined using trans-rectal ultrasonography with a 5-7.5 MHz linear array transducer (WellD ultrasound, Shenzhen well. D. Medical Electronics Co. LTD. China). Examinations were performed by trans-rectal approach according to(4). Were used to ensure that the cows are in estrus(5)

The Endometrial samples were collected by a guarded cotton swab, then transported to the laboratory at 4°C.Add 65g of sabouraud dextrose agar powder was suspended in a liter of distilled water. Bring to the boil to dissolve completely, mixed and sterilized by

autoclaving at 121°C under 15 pound/inch 2 for 15 min . and cooled to about 50°C and pour into Petri plates. Fungi were identified at genus according to macro- and microscopic criteria (6).

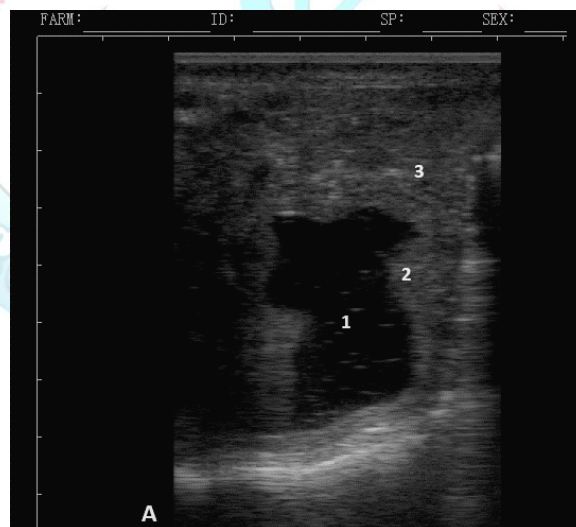The diagnosis of fungi was done by indirect method by cultured on mycological media on sabouraud dextrose agar and incubated for 7 days at 25°C. Fungi were identified at genus level according to macro- and microscopic criteria in accordance with (6). Lacto phenol Cotton Blue Stain (For fungus stain) .

Animals were divided randomly into two groups depending upon the type of treatment, each group composed of 8 cows. The first group was treated with 2gm (20ml) of oxytetracycline 10% as

intrauterine therapy; the second group 50ml of lugol's solution (0.5%) intrauterine(IU) which is ready producer from Metrizol - O.L.KAR.mhtml company .

### Results:

In our study , figure (1) show the ultrasound technique to diagnosis endometritis in cows that help the vet.practitioner more than rectal palpation ,this figure explain the disturbution of echogenic and unechogenic views to determin the endometritis of cow uterus.

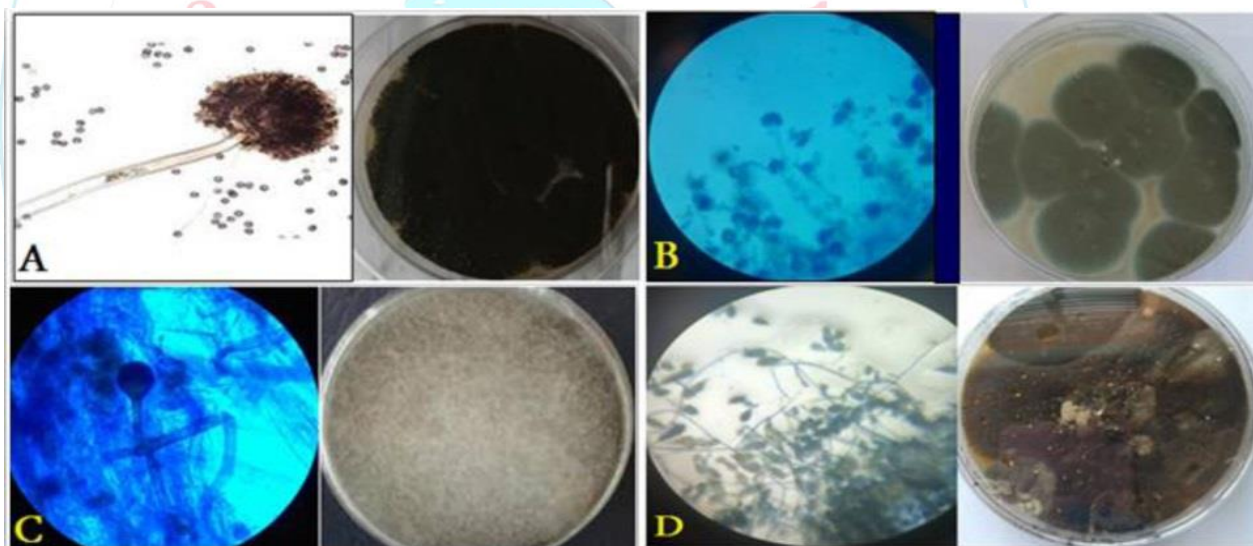


**Fig. 1** : Ultrasonographic image of endometritis(A) before treatment (probe 6.5 MHz; depth 9 cm).  
1: Purulent uterine content; 2: Endometrium;  
3: Myometrium.

The results of the highest isolation are *Aspergillus niger* , *Aspergillus fumigatus*,*Rhizopus* spp. and *Alternaria* spp.,which were (8/16,50%;6/16,37.5%;5/16,31.3% and 3/16,19%) respectively, (**table-1**) and (**figure-2**).

**Table (1): Showed different types of fungi**

	No. of sample (%)
<i>Aspergillus niger</i>	8/16(50%)
<i>Aspergillus fumigatus</i>	6/16(37.5%)
<i>Rhizopus</i> spp	5/16(31.3%)
<i>Alternaria</i> spp	3/16(19%)



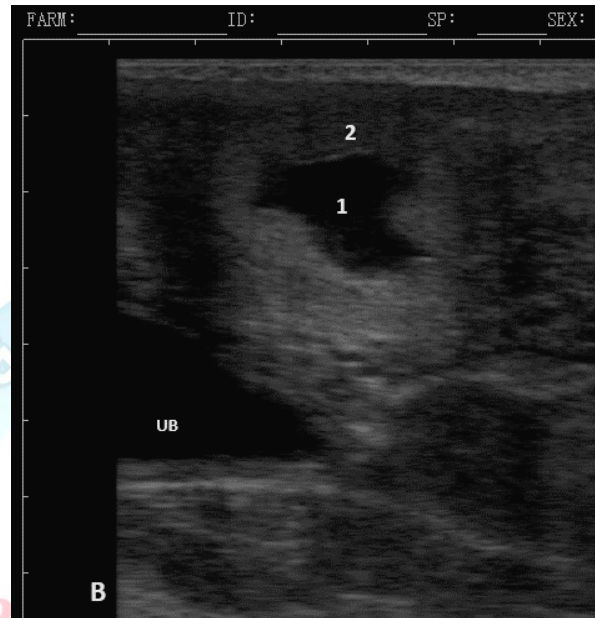
**Fig. 2:** Macroscopic and Microscopic of Fungal Isolated , by 40X , A: *Aspergillus niger* ; B:*Aspergillus Fumigatus*; C: *Rhizopus* spp; D: *Alternaria* spp.

The results of present study were illustrated in **table-2** , was showed that the responses of first and second groups

to treatment were (4/50% and 7/85.7%),respectively and the result as far as the treatment to conception were

recorded in 2<sup>nd</sup> group in comparison to the 1<sup>st</sup> group.although **figure-3** showed

the ultrasound diagnosis of endometrium and changes due to treatments.



**Fig.3** :Ultrasonographic image of normal uterus during estrus(B) after treatment (probe 6.5 MHz; depth 8 cm). 1: Accumulation of clear anechogenic content; 2: Uterine wall ;UB: urinary bladder.

**Table( 2): Different regimen of treatment and response to treatment.**

Groups	No. of treated animals	Treatment regimen	Response no. (%)
1 <sup>st</sup>	8	Oxyteracycline (20ml)	4 (50)
2 <sup>nd</sup>	8	Logul's iodine (50ml)	7 (87.7)

## Discussion

Fungus is an opportunistic pathogen that can establish in a long-term disturbed uterine or vaginal environment (7). Fungi are capable of producing reproductive failure in animals either by directly establishing infection in the reproductive system or by *in vitro* production of toxic metabolites which is later on taken up by the animal. Getting one calf per year from cattle provide maximum benefit to farmers, but when animal fails to conceive after three to four repeated inseminations in the absence of any apparent detectable abnormality, then it becomes a costly problem for dairy producers (8). These observed agree with (9).

Moreover, Lugols Iodine increases the release and metabolism of prostaglandin F<sub>2</sub> (PGF<sub>2</sub>α) from uterus(10,11). As well as stimulate myometrium contraction ,blood supply and uterine defense (12) and this effects may attributed to good response of the animals treated with logul's iodine

solution in this study. The ideal antibiotics should have ability to eliminate harmful bacteria from the uterus without damaging the uterus and impairing uterine defense mechanisms. Many studies showed beneficial effects of intra-uterine (IU) use of oxytetracycline at high doses (13), but other studies reported the non-effectiveness (14). However, current study revealed that tetracycline are still used by veterinarians for endometritis treatment in cows. These may be attributed to the oxyteteracycline is poorly absorbed from the uterus after an intrauterine infusion (15), as well as its endometrial concentration are higher and persist longer than after it has been administered by other parenteral routes . finally the ultrasound teqnuich is useful for diagnostic the difrences between the abnormal and normal view of uterus by deferant scales like uterus size ,thickness of uerine wall (16,17,18). The results revealed that most veterinarians

performed intrauterine therapy using tetracycline or other antibiotics, but not logul's iodine, which may be due to price of logul's iodine and obtainability or availability compared to tetracycline.

### References:

- 1- Sheldon, I. M.; Lewis, G. S.; LeBlanc, S. and Gilbert, R. O. (2006). Defining postpartum uterine disease in cattle. *Theriogenology*. 65: 1516-1530.
- 2- Prunner, I.; Wagener, K.; Pothmann, H.; Ehling-Schulz, M. and Drillich, M. (2014). Risk factors for uterine diseases on small and medium sized dairy farms determined by clinical, bacteriological and cytological examinations. *Theriogenology*; 82, 857 - 865.
- 3- Gilbert, R.O.; Shin, S.T.; Guard, C.L.; Erb, H.N.; Frajblat, M. (2005) Prevalence of endometritis and its effects on reproductive performance of dairy cows. *Theriogenology* ;64: 1879-1888.
- 4- Elsayed DH, El-Azzazi FE, Mahmoud YK, Dessouki SM, Ahmed EA. (2020) Subclinical endometritis and postpartum ovarian resumption in respect to TNF- $\alpha$ , IL-8 and CRP in Egyptian buffaloes. *Animal*

Reproduction.; 17(1): 1-13.

- 5- Ribeiro BLM, Junior EBSM, Reyes MAA, Marques EC, Nassar AFC, Gregory L. (2019) Assessment of the bovine uterus with endometritis using Doppler ultrasound. *BioRxiv*. doi: <https://doi.org/10.1101/826065>.

- 6- Leslie JF, Summerell BA. (2006) *The Fusarium laboratory manual*. 1st ed. Blackwell Publishing Ltd; Oxford, London:

- 7- Usmani, R.H., N. Ahmad, P. Shafi q and M.A. Mirza. (2001). Effect of subclinical uterine infections on cervical and uterine involution, estrus activity and fertility in postpartum buffaloes. *Theriogenology*, 55: 563-571.

- 8- Van Schyndel, Pascottini OB, LeBlanc SJ. (2018) Comparison of cow-side diagnostic techniques for sub-clinical endometritis in dairy cows. *Theriogenology*.; 120: 117-22.

- 9- Vallejo C, Chaves C, Benavides C, Astaiza J, Zambrano W. (2018) Occurrence of Subclinical Endometritis in Dairy Cattle and Effect on Reproductive Efficiency. *Acta Scientiae Veterinariae*.; 46: 1540.

- 10- Araujo, R. R.; Ginther, O. J.; Ferreira, J. C.; Palhao, M. M.; Beq, M. A. and Wiltbank, M. C.

(2009).Role of follicular estradiol-17beta in timing of luteolysis in heifers. Biol of Pepero.; 81(2): 426-437.

11- Lewis, G. S. (2003). Role of ovarian progesterone and potential role of prostaglandin.J Anim Sci.; 81:285-293.

12- Galvao, K.N.( 2013). Uterine diseases in dairy cows: understanding the causes and seeking solutions. Anim. Reprod. 10(3), 228-238.

13- Hamza, R.; Alessandro, R.; Ahmed K.L. and Christian ,H. (2019) . Methods of diagnosis and treatment of postpartum uterine infection adopted by Algerian veterinarians. Turk. J. Vet. Anim. Sci ;43: 218-228.

14- Souhayla, O. H.;Sulake ,F.A.; Monther, A.(2013). Different Endometritis Treatments in Ewe: Comparative Study. *Journal of Agriculture and Veterinary Science*; 3(5):91-94.

15- Coto RM, Lucy MC.(2018) Uterine inflammation affects the reproductive performance of dairy cows:

A review. *Agronomia Mesoamericana*.; 29(2): 449-68.

16- Kelly E, McAloon CG, O'Grady L, Duane M, Somers JR, Beltman ME.(2020) Cow-level risk factors for reproductive tract disease diagnosed by 2 methods in pasture-grazed dairy cattle in Ireland. *J Dairy Sci.*;103:737-49.

17- Barlund CS, Carruthers TD, Waldner CL, Palmer CW.(2008) A comparison of diagnostic techniques for postpartum endometritis in dairy cattle. *Theriogenology.*;69:714-23.

18- Yaseen Mahmood Rasheed , Mohammad Yousif Mahmood and Salah Noori Mohammed (2023). Real-Time Ultrasonic Diagnosis of Pseudopregnancy in Goats and Treatment with Prostaglandins, *Diyala Journal for Veterinary sciences*;1(4):127-135.