

## Significance of Fast in Blunt Abdominal Trauma

Amir Hinbis Masawod (FICMS,CABS)<sup>1</sup>, Hazim Jabbar Kashtal (FICMS)<sup>2</sup> and  
Ahmed Modher Khalaf (FICMS)<sup>3</sup>

### Abstract

**Background:** Blunt abdominal trauma is a common problem in our country. Some of the cases had been explored on no bases which were negative by FAST (focused assessment with sonography of trauma). FAST is a tool to detect intra-abdominal collection.

**Objective:** To appreciate the value of (FAST) in blunt abdominal trauma.

**Patients and Methods:** This study performed by a collection of 100 cases of blunt abdominal trauma admitted to the emergency department at Baquba Teaching Hospital from the period 1<sup>st</sup> January, 2013 to 31<sup>st</sup> December 2013 fast performed on all cases to detect any intra-abdominal collection, then correlation with this result and laparotomy or conservative results.

**Results:** Out of 100 patients, Twenty seven cases had intra-abdominal collection and seventy three cases had no intra-abdominal collection by fast, 27 cases were positive and one case false positive and 73 cases were negative and 2 false-negative results and 71 true negative. The sensitivity was 92.8 % and specificity 98.6%. The positive predictive value was 96.2 % and negative predictive value 97.2 % and the accuracy 97 %.

**Conclusion:** Focused assessment sonography of trauma can detect intra-abdominal fluid accurately and rapidly, FAST potentially valuable tool for better assessment of trauma in the emergency department.

**Keywords:** Focus assessment with sonography of trauma (FAST), blunt abdominal trauma, abdominal emergency

**Corresponding Author:** Amirmas60@gmail.com

**Received:** 15<sup>th</sup> September 2020

**Accepted:** 20<sup>th</sup> October 2020

**DOI:** <https://doi.org/10.26505/DJM.19025620915>

<sup>1,2</sup> Al\_karh General Hospital- Baghdad- Iraq

<sup>3</sup> College of Medicine-University of Diyala -Diyala-Iraq

## Introduction

Blunt abdominal trauma makes up to 75% of blunt trauma, 70% of trauma by a road traffic accident, steering wheel, dashboard or a seat belt, causing contusion of solid organs in less serious cases, or rupture internal organ injury. Two basic physical mechanisms will play with potential injury to intra-abdominal

organs, compression and deceleration, liver and splenic trauma followed by small intestine are at risk[1].

Ultrasound has been in widespread use in the United States of America for over 20 years. portable ultrasound was developed in the 1990's with low-cost and high-quality

machines. The FAST is a four-view scan that relies on detecting presence of fluid, within the pericardium and most dependent zones of the peritoneum in the supine patient. It is capable of detecting more than 100-250ml of free fluid. CT scanning, in comparison, can detect more than approximately 100ml of free fluid in the abdominal cavity.

It is used for patients with blunt abdominal trauma whether hemodynamically stable or not. FAST has a limitations:

1. It is not as sensitive as CT in identifying solid organ injury.
2. It depends on the indicator of free fluid within the peritoneum to identify significant hemorrhage. Haemoperitoneum is not present in all patients with abdominal visceral injuries [2].
3. The scan should be repeated during the secondary survey and also if the patient has clinical deterioration[2].

The risk of negative exploration in false-positive cases, and cases being on the conservative measure (false negative) can be minimize if FAST done properly with good clinical examination and close chart observation.

Ultrasonographers used standardized procedure on a bedside ultrasonography unit (Shimadzu 600) with a 3.5 MHz Convex probe, to examine supine patients with their bladder filled ,either before catheterization or by temporary clamping of Foley's catheter or filling the bladder with 200-300ml of sterile saline through the Catheter. So it is used widely in nearly all major hospitals and trauma centers to evaluate patients with blunt abdominal trauma to decrease the rate of negative laparotomy.

All trauma patients are assessed and managed according to the ATLS guidelines. Information from the primary survey combined with examination of the abdomen is used to detect the likelihood of possible injuries and tailor management plans. Abdominal pain/tenderness together with observations such as blood pressure are used in the assessment to detect injury, however, a limitation of this is that large amounts of blood can build up in the peritoneum before such positive signs and symptoms can be detected on physical examination alone.

There is some evidence to suggest it can detect as little as 30 ml of free fluid, but 100 ml is generally considered to be the level at which FAST scanning is accurate. Knowing that a patient has free fluid suggests the possibility of severe intraperitoneal hemorrhage and supports the case for further management, such as an emergency CT and/or surgery. Haemodynamically stable patients may be sent for CT scanning in order to assess the origin and extent of injury so as to achieve prompt and appropriate management, whilst hemodynamically unstable patients may be taken directly to the operating theatre for emergency laparotomy where a lack of formal, comprehensive imaging could potentially lengthen the theatre time as the site and extent of the injury is unknown.

FAST's ability to detect free fluid rapidly and in a non-invasive manner has made it more attractive than other 'in department' tests such as diagnostic peritoneal lavage which carries risks of perforation, infection and bleeding. Despite the apparent ease of use and accessibility, the accuracy of FAST

scan is related to the machine, the operator and the patient. Body shape, obesity and surgical emphysema can make scans difficult to perform and without a skilled operator, FAST has the potential for misinterpretation or, misdiagnosis.

Despite the popularity of FAST, there remains a lack of clarity and evidence around any actual contribution to patient survival. No prospective trials have been performed in relation to FAST scanning and so it has been adopted into current practice with the entire evidence base being retrospective. The

implications of this are that we are still learning how effective it is, both as a diagnostic tool and in changing the management of patients.

### Patients and Methods

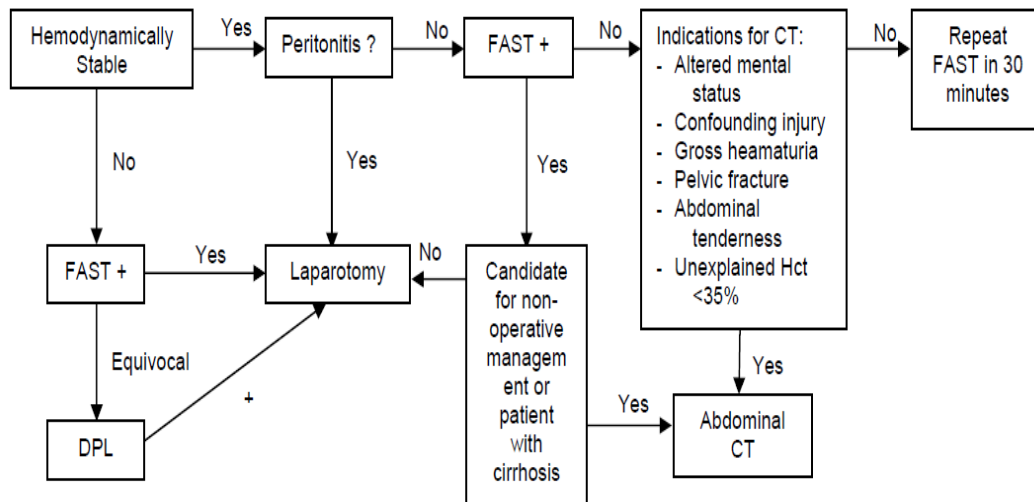
This study was conducted on 100 consecutive patients in emergency casualty at Baquba Teaching Hospital during the period between January 2013 to December 2013. The age range (5-66) years males are 66 (66%), females are 34(34%), man to women ratio 1.8:1 Table (1).

**Table (1):** Gender incidence

Patient sex	Number	Percentage
Male	66	66%
Female	34	34%

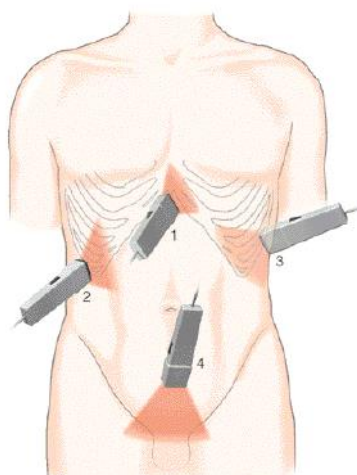
The patients were initially evaluated by a physical examination to assess their hemodynamic stability, and then underwent FAST regardless of the physical examination results, followed by either conservative or

operative treatment. according to the whole data collected. After permission from Matthew, This algorithm helps to asses the patient.



Patients were prepared for FAST by lying supine, full exposure of the abdomen, cleaning the skin with saline-soaked gauze; we apply to the abdomen contact gel. The FAST examination was undertaken during

the first 30 minutes of patient's arrival, including the four acoustic windows (pericardiac, perihepatic, perisplenic, pelvic).



**Figure(1):** Showing four views used in fast scan after permission of Matthew

A format already prepared for the patient were filled including the I.D and the result of FAST and operative finding if any. To assess the presence of free fluid in the abdomen or pelvis. Findings were considered positive if free fluid of any amount was found in the abdominal or pelvic examination, regardless the solid organs parenchyma status. Patients then followed till discharge from the hospital, whether the patient was treated conservatively or operatively.

### Statistical analysis

P-value by statistical software known as Medcale, at P equals to or less than 0.05 the results were considered as significant.

### Results

During one year study, 100 cases of blunt abdominal trauma were collected, their age range(5-66)years, males 66 (66%), females are 34(34%); male to female ratio 1.8:1. Among the total number of cases, 31% of them were isolated abdominal trauma, while 69% were associated with other concomitant injuries Including head, thoracic, and extremity injuries; as most of our victims suffered from insults that trigger multiple injuries rather than Abdominal alone.

**Table (2):** Shows the mechanism of injury of the collected cases

Mechanism of injury	Number of cases	Percentage
RTA	71	71%
DIRECT BLOW	11	11%
FFH	18	18%
TOTAL	100	100%

Out of 100 patients, 73 were found negative by FAST, 2 cases were false negative as one of them was complaining from trivial visceral injury discovered during operation & the other one had a significant amount of intra-peritoneal free fluid that was not detected by FAST. The twenty-seven FAST positive cases included 26 patients who underwent exploratory laparotomy with positive findings, 12 of these patients were suffering from isolated injuries to the spleen

ranging from a simple splenic tear to splenic avulsion, other 5 cases with positive laparotomy suffered from splenic tear plus retroperitoneal hematoma due to renal injuries. Another 5 patients who underwent laparotomy noticed to have liver lacerations that were repaired by simple suturing. The remaining 4 cases had a mesenteric injury, bladder rupture, and visceral injuries collectively.

**Table (3):** Result of negative study (fast negative)

category	hemodynamic		Physical examination		Fast examination		Total
	stable	unstable	significant	not	False negative	true negative	
Negative	73	0	0	73	2	71	73

**Table (4):**Result of positive study(fast positive)

category	hemodynamic		Physical examination		Fast examination		Total
	Stable	unstable	significant	not	True positive	False positive	
Positive	15	12	20	7	26	1	27

Among all the included cases, 88 of them were hemodynamically stable during the primary survey, and only 12 of them were unstable and required immediate surgical intervention after FAST had been performed. The sensitivity and specificity of FAST were

92.8% and 98.6% respectively, Negative Predictive Value was 97.2%, and Positive Predictive Value was 96.2%, while the overall accuracy was 97%. Table (5) shows statistical values of the collected data.

**Table (5):** Comparisons between the results of current study and others

study	Number of cases	Sensitivity%	Specificity%	Npv%
Current Study (2014)	100	92.8%	98.6	97.2
Nural (2005) [3]	454	86.5	95.4	98.7
Holmes (2004) [4]	447	79	95	93
Miller (2003) [5]	359	42	98	93
Matteu (2001) [6]	2576	86	98	98
Mckenney (2001) [7]	996	88	99	98
Coley (2000) [8]	107	55	83	50
Boulanger (1999) [10]	400	81	97	96
Shackford (1999) [11]	234	69	98	98
Chiu (1997) [12]	772	71	100	78

## Discussion

Many researchers demonstrated the benefit of FAST to detect intra-abdominal injuries. In our study; the results nearly matched those from previous studies in regard to their statistical values.

Nural (2005) [3], Matteu (2001) [6], and Boulanger (1999) in their similar studies compared the FAST scan with the final outcome of total patients, whether they were treated conservatively or surgically. They revealed high sensitivity, specificity to detect intra-peritoneal collections, when compared with the current study results; they were nearly identical, as the nature of our study resembles their previous ones. On the other

hand, the rest of the studies that compared FAST scan result to the results of other parameters being used to assess abdominal trauma, including DPL, CT-Scan, showed less similar statistical results to our study, this could be explained that; the factors that may limit or disable FAST to detect intra-abdominal injuries did not fully have experience at that time comparing FAST scan to other higher sensitive and specific investigation There are 2 False Negative

cases in our study; one of them experienced changes in the clinical presentation and persistent abdominal pain during the period of observation led to exploratory laparotomy which showed small bowel perforation, and as demonstrated in many international studies, that FAST scan may be unable to detect certain injuries, for example; bowel perforations, mesenteric injuries, retroperitoneal organ injuries, and diaphragmatic injuries, thus this case can be accepted[7]. Only one false positive case was recorded in our study, this case showed to have a free intraperitoneal fluid collection by fast and later on needs laparotomy. Such case fluid in the stomach or the bowel can be mistaken as a free intra-abdominal collection [9]; which make us did explorative laparotomy for him, that is why it is mandatory to correlate FAST results with the general condition of the patient.

## Conclusions

FAST scan has the advantages of being rapid, noninvasive, reproducible, readily available, easy to learn, and accurate, with high sensitivity & specificity; listing it at the top of the screening tests to evaluate patients



with blunt abdominal trauma. However, FAST has own limitations of being subjective, and miss certain types of injuries.

### Recommendations

Fast reduce the incidence of negative laparotomy so it must be done for every patient who is obscure.

### References

- [1] Jonsen J, Loadon MA, investigation of blunt abdominal trauma. *bmj*. 2008 April;336(7650):938-42.
- [2] Rodriguez C, Barone JE, Wilbanks TO, Rha CK, Miller K. : Isolated free fluid on computed tomographic scan in blunt abdominal trauma: a systematic review of incidence and management. *Trauma*. 2002 Jul; 53(1):79-85.
- [3] Nural MS, Yordan T, Guven H, Baydin A, Bayrak IK, Kati C: Diagnostic value of ultrasonography in the evaluation of blunt abdominal trauma. *Diagn Interv Radiol*, 2005 Mar, 11(1):41-4.
- [4] Holmes JF, Harris D, Battistella FD: Performance of abdominal ultrasonography in blunt trauma patient without emergency department hypotension. *Ann Emerg Med*, 2004 Mar, 43(3):354-61.
- [5] Miller MT, Pasquale MD, Bromberg WJ, Wasser TE, Cox J: role of FAST. *J Trauma*, 2003 Jan, 54(1):52-9.
- [6] Matthew, Dolich MO, McKenney MG et al: Ultrasounds for blunt abdominal trauma. *Trauma*, 2001, 50(1):108-12.
- [7] McKenney KL, McKenney MG, Mark G, Cohn SM, and Compton R: Hemoperitoneum score helps determine need for therapeutic laparotomy. *Trauma*, 2001, 50(4):650-56.
- [8] Coley BD, Mutabagani KH, Martin LC et al: Focused abdominal sonography for

- trauma (FAST) in children with blunt abdominal trauma. *Trauma*, 2000, 48:902-6.
- [9] Brock Schendler, BJ Cruise, Jackop Suise, American College of Emergency Physicians: Policy statement•Emergency ultrasound imaging criteria compendium, 2007 Feb, 12, 26.
- [10] Boulanger BR, McLedlan BA, Brenmenan FD, Ochoa J, Kirkpatrick AW: Prospective evidence of the superiority of a sonography-based algorithm in the assessment of blunt abdominal injury,. *Trauma*, 1999, 47:632-37.
- [11] Shackford SR, Rogers FB, Osler TM et al: Focused Abdominal Sonogram for Trauma: the learning curve of nonradiologist Clinicians in detecting haemoperitoneum, *Trauma*, 1999, 46(40):492-98.
- [12] Chiu WC: Potential limitation of FAST. *Trauma*, 1997, 42(4):617-22.