

PATHOLOGICAL STUDY AND GENETIC DIAGNOSIS OF VINBLASTINE EFFECTS ON DNA OF OVARY AND TESTES IN MOUSE

Muna Sachit Hashim^{1,4}

Suad Abdul-Kareem Mohammed¹

Rabab Abd Almeer Naser²

Thikra Abdulla Mahmood³

Taghreed Jabbar Humadi¹

¹Dept. of Pathology, College of Vet. Med., University of Baghdad, Iraq.

² Dept. of Anatomy, College of Vet. Med., University of Diyala, Iraq.

³ Dept. of Community Medicine, College of Medicine, Kufa University, Iraq.

⁴Corresponding author: sachitmuna@yahoo.com

ABSTRACT

The present study was designed in order to identify the effects of vinblastine on ovary and testes and then on fertilization capacity and pregnancy outcome in white mice, fifty mixed mice were used, 10 treated male were mated with 10 untreated female, 10 untreated male were mated with 10 treated female, and (10) mixed mice as control. Results of male test showed decline in sperm count with spermatocytes' morphological deformity. The results of molecular technique applied on testicular section and ovarian section, showed that green signals, indicating the damage on TK (11qE2)/XY gene on chromosome of sperm and ova, red signal indicate intact gene yellowish signals indicated translocation on the same gene (mutation). Pathological findings showed marked loss of spermatogenesis (Azoospermia) with damage in testes' tissues; fibrosis of ovarian stroma with degenerative changes on ovary and evidence of early embryonic death with absence or low fertility.

Key words: Vinblastine, mouse, DNA, ovary, testes.

INTRODUCTION

Vinblastine belongs to a group of medications known as vinca alkaloids and is obtained from the plant *vinca rosea*. Vinca alkaloids act as antimicrotubule agents that block mitosis by arresting cells in the metaphase. In Veterinary medicine, this agent represents the treatment of choice for canine transmissible venereal tumor (CTVT). The treatment is effective for 90% of CTVT cases, by intravenous (IV) administration, at the dose of 0.5-0.7 mg m⁻² of body surface, once a week (Withrow, 2001). Vinblastine is safe for most patients, but potential side effects can occur, as gastro- intestinal alterations, myelosuppression and extravasation injury (Said, 2009) vinca alkaloids caused neurotoxicity involve peripheral, autonomic and central neuropathy (Graf, 1996). Neurotoxicity can persist for months after discontinuation of therapy in some patients, and in rare cases may be disabling (Egbelakin, 2011). Infants and embryos are at a higher

risk for experiencing Vinblastine-related neurotoxicity (Haskell, 1995). Peripheral neuropathy is the most common type of neuropathy and develops in almost all patients (McEvoy, 2004). Loss of deep tendon reflexes, peripheral paresthesia, pain and tingling can occur. If therapy is prolonged or high doses are administered, wrist and foot drop, ataxia, a slapping gait and difficulty in walking can occur. Cranial nerve toxicities may lead to vocal cord paresis or paralysis (hoarseness, weak voice), ocular motor nerve dysfunction (ptosis, strabismus), bilateral facial nerve palsies, or jaw pain. Severe jaw pain can occur within a few hours of the first dose of Vinblastine. Autonomic neuropathy results in constipation (which can be severe), abdominal pain, urinary retention and paralytic ileus. Central neuropathy includes headache, malaise, dizziness, seizures, mental depression and psychosis (Perry, 2001).

Vinca alkaloids effects fertility

Chemotherapeutic agents can initiate accelerates the reduction of the primordial follicle pool, induces ovarian atrophy and further a destruction of vascularization of the ovary which leads to ovarian damage and risk of premature ovarian failure, Follicular apoptosis and cortical fibrosis of ovaries are also assumed effects related to treatment with chemotherapy (Meirow, 2010). Vinblastine therapy in female mouse caused defects in primary and secondary follicles and corpus luteum with in depression follicular stimulating hormone (FSH) and luteinizing hormone (LH) and estrogen and progesterone (Al-Ahmed, 2010). Vinca alkaloids crossed the blood-Placenta barrier to produce cellular changes might play an important role in initiating growth defects and dead of embryo (Joneja, 1969 ; Hejazi, 2012). Vinca alkaloids reduced fertilization ability of male mice as results of DNA damage of sperm and so lead to sterile mating or pseudo-dominant-lethal effects. Researcher found that mice with vincristine treated father had a mutation rates up to twice that of mice with untreated fathers notably, these mutations were present in DNA inherited from both treated father and untreated mother, what this likely means according to the researches measures is that chemotherapy induces epigenetic changes in the sperm. Epigenetic Changes do not affect underlying DNA sequence but they alter chemical tags that control how genes are expressed this in turned to genome destabilization in the offspring, following sequence mutation to arise in DNA from the mother or father. The exact mechanism for genome destabilization and how it's inherited is unknown (Sarah, 2012). Suggesting impairment of epididymis function particularly concerning sperm maturation and endocytosis removal of contents of the cytoplasm droplets and

dead sperm (Averal, 1996). Male mouse treated with Vinca alkaloids for four separated period 2, 4, 6 and 8 weeks suffered from gradually loss of testes weight, sperm count, spermatocytes abnormalities with sever histopathological lesions on testes tissue represented by loss of spermatogenesis and dead sperm from apoptosis with inflammatory reaction further to necrosis (Al-Aamery, 2013).

MATERIALS AND METHODS

Fifty mixed mice were kept in animal house of Veterinary Medicine College in Baghdad and fed on pellet for laboratory animal and provide with tap water in special tubes, 10 male and 10 female were injected with Vinblastine I/P (0.1 mg 10 gm⁻¹ b.w) (Al-Aamery, 2013).

For one month (4 weekly injection) and mated with 20 mixed untreated mice in separated groups. Other 10 mixed mice remained as control. After scarified animals, sperm specimens collection directly from epididymis and direct seminal fluid analysis was done (Al-Aamery, 2013).

(Cooper, 2010). Testes and ovary section were prepared on a charge slides for molecular examination by using of FISH procedure to identify DNA damage on spermatocytes according to (Al-Aamery, 2013 ; Wyrobek, 2005 ; Galina, 2010). Tissue specimen's testes and ovary were prepared for paraffin embedded sectioning and histopathological processing with staining methods was done (Slaoui, 2011).

RESULTS AND DISSCUSION

Results of fertility parameters in male and female

The results of seminal fluid analysis showed in table 1, that there was rapid decrease in spermatocytes count with evidences of morphological deformities and loss of testes weight. The results of molecular test showed in table 2 that there was gradual and marked damage in DNA of sperm after 1st week of treatment with Vinblastine and be more evident after 4th week of treatment. The results of fertility parameters in females' mouse after treatment with Vinblastine showed in table 3, that there was loss of ovarian weigh with bad pregnancy outcome and visible loos in newborn with premature death of fetuses.

Table 1. Male fertility test

| Group and treatment time n=10 | Sperm count $\times 10^6 \pm$ s.d | Abnormal spermatozoa % \pm s.d | Testes mean weight (mg) \pm s.d |
|-------------------------------|-----------------------------------|----------------------------------|-----------------------------------|
| 1- 1st week | 5.18 \pm 1.21A | 22.5 \pm 10.1C | 361 \pm 25.6 a |
| 2- 2nd week | 4.30 \pm 0.63B | 30.1 \pm 11.4C | 302 \pm 35.6 B |
| 3- 3rd week | 2.16 \pm 1.43B | 47.5 \pm 11.7C | 202 \pm 38.0 B |
| 4- 4th week | 1.28 \pm 0.63B | 61.2 \pm 17.3C | 108 \pm 33.6 B |
| 5- Control | 6.15 \pm 1.22 | 13.4 \pm 1.04 | 422 \pm 25.6 |

Table 2. Molecular test for detection of DNA damage in ovary and testes

| Group and treatment time n=10 | Percentage of spermatocytes' DNA damage ((% \pm s.d) with 3 score (Red, Green, Yellow) in ovary | | | Percentage of DNA ovary (% \pm s.d) with 3 score (Red, Green, Yellow) in testes' tissue | | |
|-------------------------------|--|---------|---------|---|--------|-------|
| | Score1 | score 2 | score 3 | score1 | score2 | score |
| 1-1 st week | 6 | 2 | 2 a | 3 | 4 | 5 a |
| 2-2 nd week | 3 | 3 | 4 a | 2 | 4 | 5 a |
| 3-3 rd week | 2 | 3 | 5 a | 1 | 6 | 3 A |
| 4-4 th week | 0 | 2 | 8 A | 0 | 1 | 9 B |
| 5- Control | 8 | 2 | 0 | 9 | 1 | 0 |

Differences from control are assessed by analysis of variance. Significant at: a: $p < 0.05$; A: $p < 0.01$; B: $p < 0.001$ and assessed by the χ^2 test C: $p < 0.001$. Damage on DNA assessed as: Score 1 (0-20%); score 2(20-50%); score 3(50- above 95 %).

Table 3. Females tested: for pregnancy outcome

| Group and treatments' time n=10 | ovary mean weight (mg) \pm s.d | Pregnant female % | Live fetuses | Dead fetus | Fertility % |
|---------------------------------|----------------------------------|-------------------|--------------|------------|-------------|
| 1-1st week | 430 \pm 12.5 | 8 (80%) | 78% | 22% | 62% a |
| 2- 2nd week | 333 \pm 0.9 | 6 (60%) | 56% | 44% | 33% a |
| 3- 3rd week | 187 \pm 2. 6 | 3 (30%) | 41% | 59% | 12% a |
| 4-4th week | 102 \pm 1.25 | 1 (10%) | 22% | 88% | 2.2% a |
| 5-cotrole | 545 \pm 11.6 | 10(100%) | 95% | 5% | 95% a |

Differences from control are assessed by analysis of variance. Significant at: a: $p < 0.05$.

Vinblastine caused early loss of spermatogenesis with incidence of sperm defects and heavy drop in testes weight after few week of treatment that's' proved and agreed with Al-Aamery (2013) and Dobrzynska (2003) in the same family of drug uses. As well as agreed with Marvin (2013) who said that's chemotherapy causes reduction of sperm counts often to azoospermic levels that may persist for several years or be permanent. Females of mouse suffered from ovarian loss of weight due to ovarian hypoplasia with increase percent of immature deliver baby with dead or defected fetuses that's' lead to pad

pregnancy outcome and this agreed with (Hejazi, 2012). Who said that the similar family drug vincristine has teratogenicity effects on the fetus as well as clinical effects. Also agreed with studies based on the penetration of the drug through blood-fetus and the cause of birth defects (Aigraina, 2005 ; Sadler, 2000).

Results of microscopic appearance

1-Molecular examination: was done by the application of florescence's in situ hybridization (FISH) method and procedure on mouse samples testes and ovary according to (Al-Aamery, 2013). Green signals in testes and ovary represented the damage in site of TK (11qE2) / XY gene of sperm; Yellow signals refer to mutation or translocation in the gene. Red signal represented the controls' sample Figure 1 "A, B, C and D".

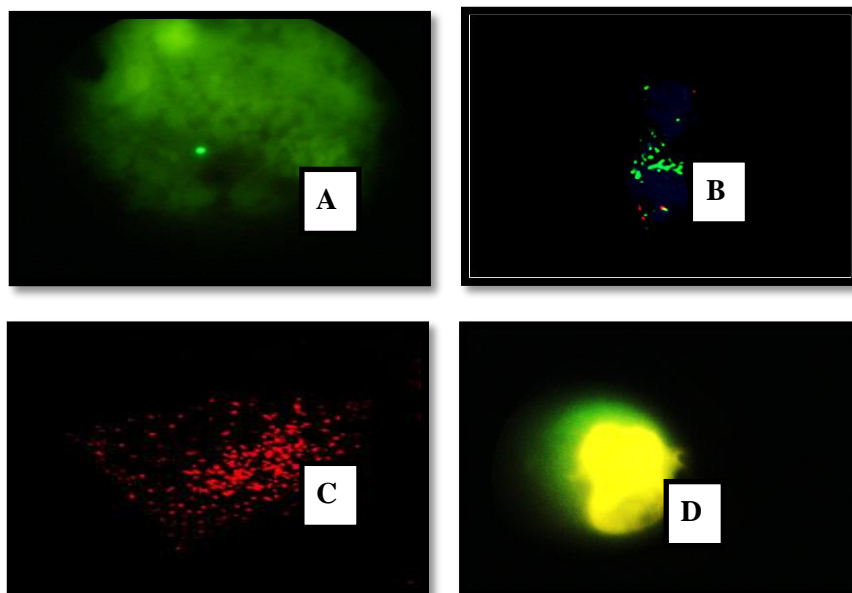


Fig. 1. A. testes section B. ovary section C. red signal of control D. yellow signal

The results of molecular test (FISH) examined the defect on DNA of spermatocytes and ovary by calculating signals' percent referring to chromosomal damage on TK (11qE2) /Y gene of sperm and ovary. Results agreed with Al-Aamery (2013) who study the same effects of vincristine on DNA'S sperm of mouse and with Wyrobec (2005) who use the same test.

2- Histopathological examination

Testes sections shows empty of seminiferous tubules (A) due to loose of spermatogenesis with degenerative changes represented by hydropic degeneration (B) with necrosis involve dead sperm and endothelial cells falls into lumen (C) figure 2. In comparison with normal seminiferous filled tubules (Figure 3).

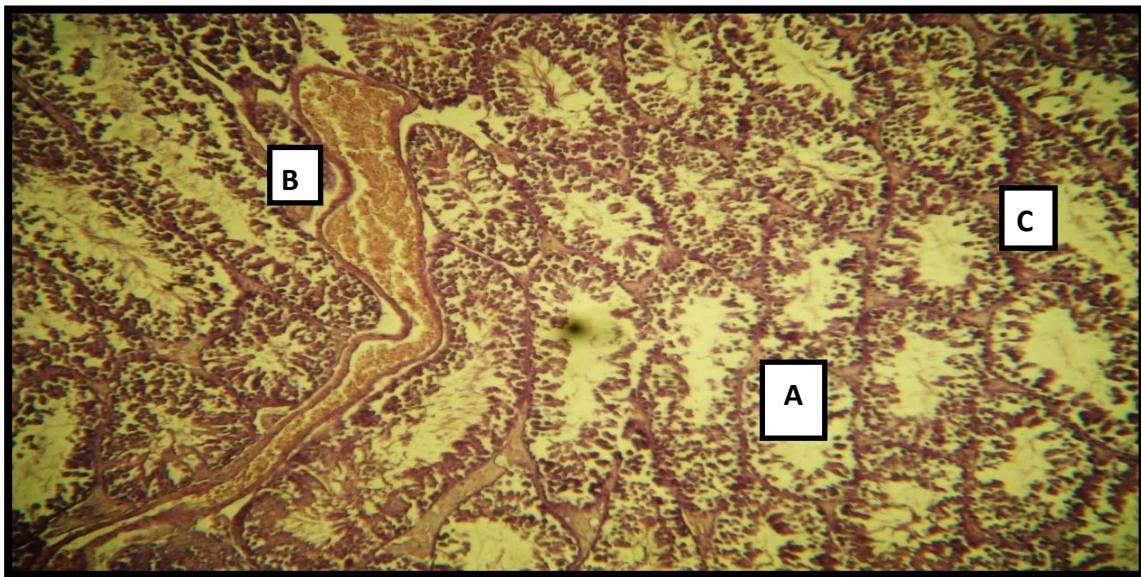


Fig. 2. Testes treated with Vinblastine showed empty seminiferous tubules (A) refer to loss of spermatogenesis, with dilated and congested blood vessel (B) and necrosis (C) (H&E 40X)

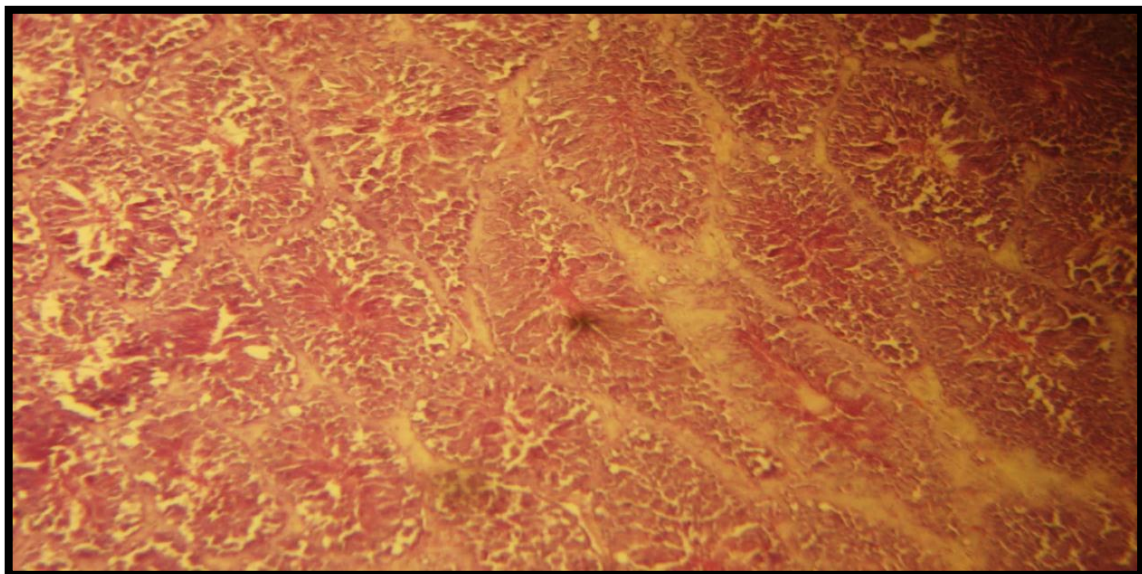


Fig. 3. Testes (control) showed spermatocytes filled seminiferous tubules (H&E 10X)

The pathological finding of females sections showed, that there's an evidence of uterine fibrotic lesions involves endometrium (Figure 4. "A and B"). With atrophic and necrotic endometrial glands with glandular' epithelial lining metaplasia and hyperplasia (Figure 5. "A and B"). Ovarian section of mouse showed failure of ovulation at the end of 4 week of treatment with Vinblastine with fibrotic lesions involves primary and secondary follicles within ovarian stroma and hydropic degeneration (Figure 6).

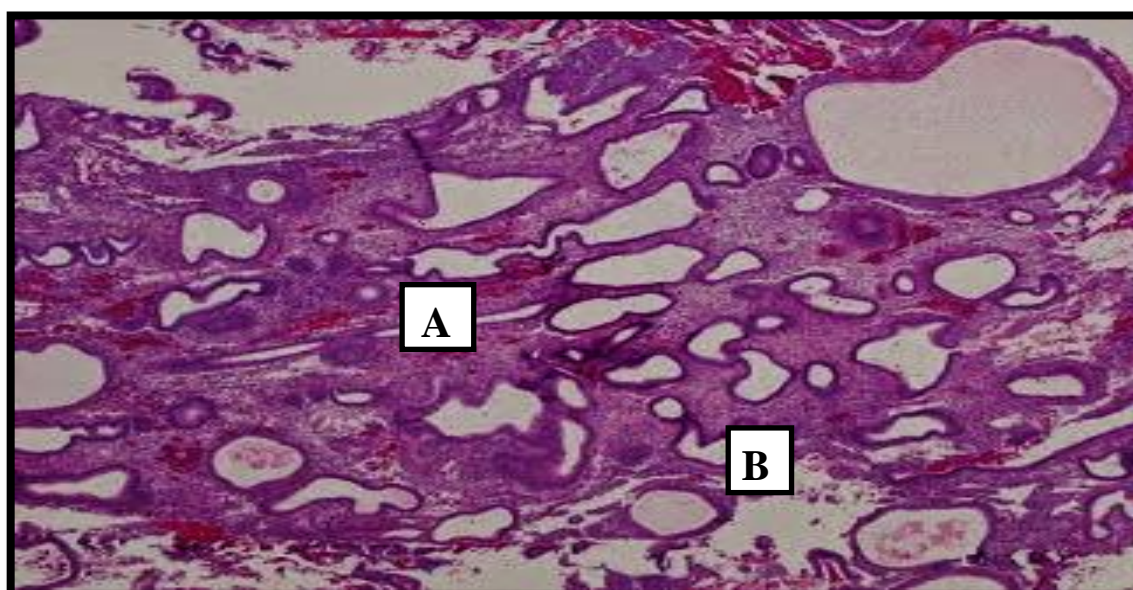


Fig. 4. A. Uterus section of mouse showed cystic edematous degenerated endometrial gland (A) with coagulative necrosis (B) (H&E 10X)

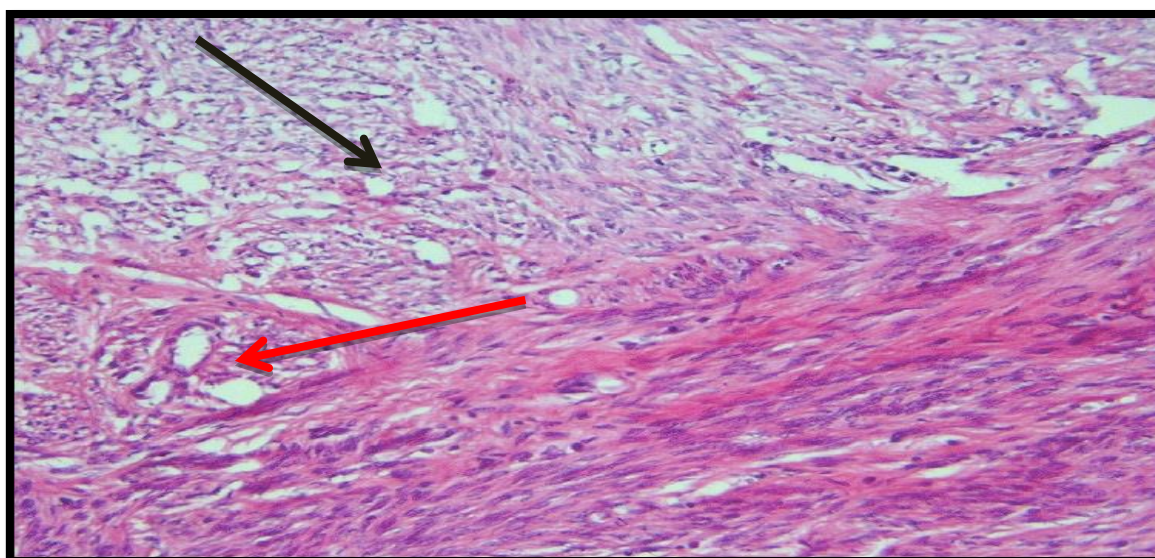


Fig. 4. B. Uterus section of mouse showed fibrosis (Black arrow) and comprised atrophic degenerated glands (Red arrow) within endometrium (H&E 40X)

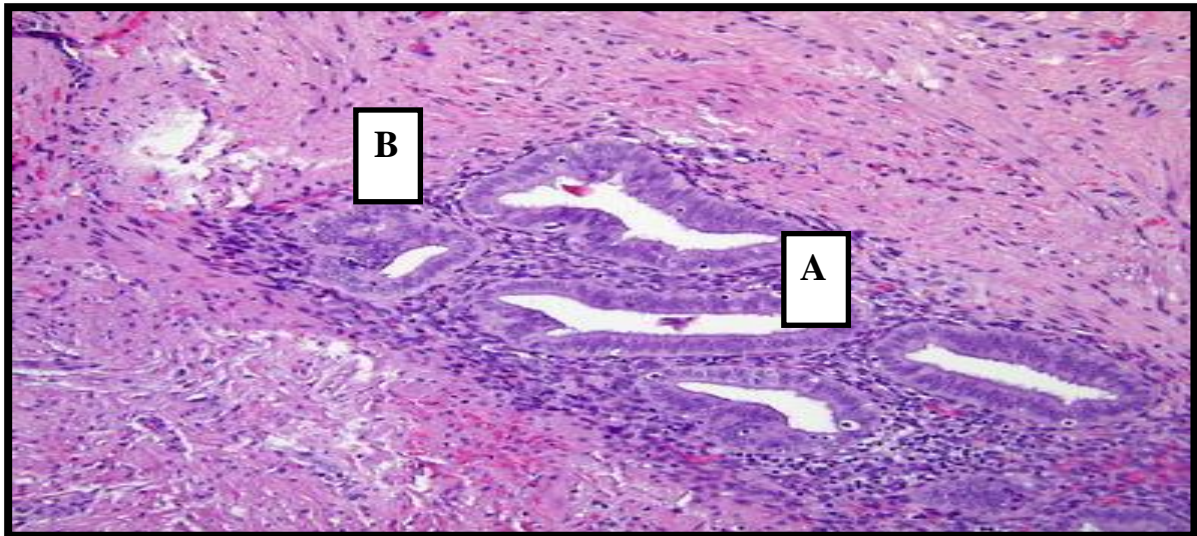


Fig 5. A. Uterus showed atrophic and necrotic endometrial glands (A) with glandular lumen epithelial lining (B) metaplasia and hyperplasia with papillary projection (H&E 10X)

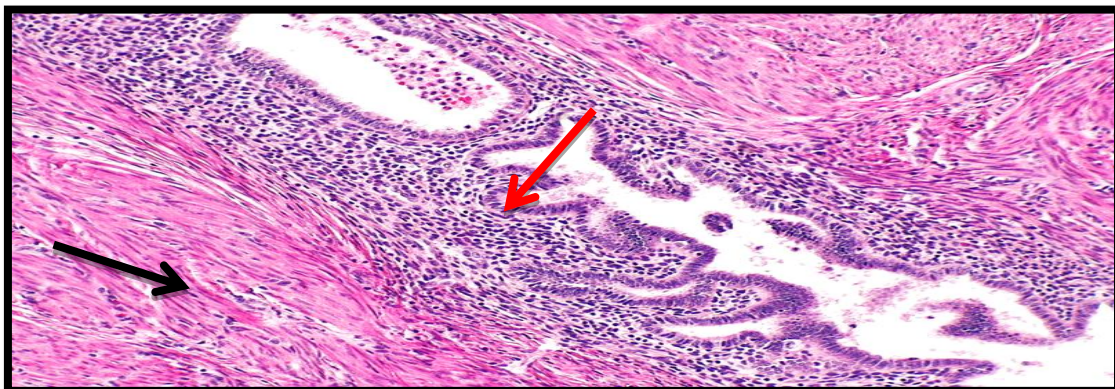

Fig. 5. B. Uterus showed vacuolated glands (black arrow) with glandular lumen distention with papillary projection from metaplasia and hyperplasia (Red arrow) (H&E 10X)

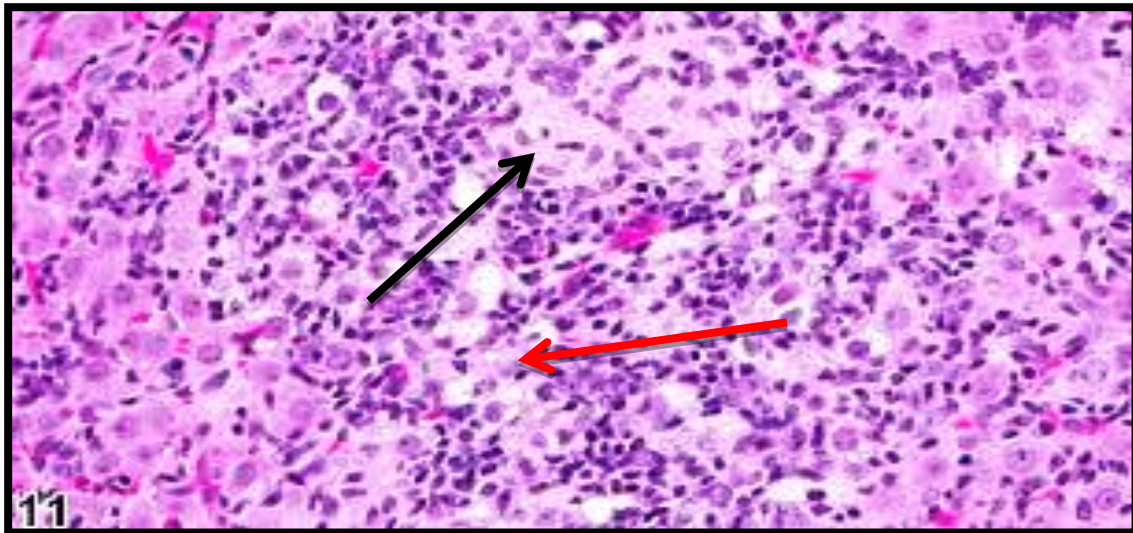


Fig. 6. Ovarian showed early degenerative changes on follicles with failure of ovulation (Red arrow) at the end of 4 week of treatment with vinblastine; fibrotic lesions (black arrow) involves ovarian stroma with hydropic degeneration (A) (H&E 40X)

Vinblastine has toxic effects on mouse reproductive organs represents by losing of spermatogenesis, vacuolation and necrosis within seminiferous tubules and fibrosis in an advance stages, this effects increased with increased time of treatments, and attributed to the pharmacokinetic factor of drugs that's caused early pass of drug through blood testes barrier (BTB) and exerts it's toxicity as soon as contact with testicular cells mainly leydig cells, sertoli cells, germs cells so there's' evidence of oligospermia, azoospermia, and germinal aplasia. This study's' results agreed with what found by (Al-Aamery, 2013 ; CC Lu,1979 ; Roeser, 1998 ; Fairly, 1999). In female we found that s' vinblastine caused severe fibrotic lesions within atrophic uterus and ovary, that's caused failure in successful fertilized ova due to lose of mature follicles, lead to bad outcome of pregnancy which increased with increased time of treatment. Beside the immature parturition or early delivery with dead or defects fetuses. And this agreed with Hejazi, 2012 ; Dobrzyńska, 2005 ; Karen, 2009).

CONCLUSION

A chemicals drug affects both histological and genetics structures of ovary and testes.

REFERENSSES

Aigraina, E. J. and G. Korenb. 2005. Effects of drugs on the fetus. *Seminars in Fetal and Neonatal Medicine*, 10: 139-147.

- Al-Aamery, Muna, S. H. 2013. Molecular, Pathological and Immunological Study of Vincristine Sulfate Effects in White Male Mice and Rats. Pp: 59-154. Ph. D. Thesis. College of Vet. Med., University of Baghdad.
- Averal, H. I., A. Stanley, P. Murugaian, M. Palanisamy and M. A. Akbarsha. 1996. Specific effect of Vinca alkaloids on epididymis. *Indian. J. Exp. Biol. Jama*: 34: 53-60.
- CC Lu and M. L. Meistrich. 1979. Cytotoxic effects of chemotherapeutic drugs on mouse testis cells. *Cancer Research (Impact Factor: 8.65)*. 10/1979; 39(9): 3575-82, source: Pub Med.
- Cooper World Health Organization. 2010. Department of Reproductive Health and Research world health organization Laboratory Manual For the Examination and processing of human semen 5th ed, world health organization, Geneva, Switzerland.
- Dobrzyńska, M. M., U. Czajka and M. G. Słowikowska. 2005. Reproductive effects after exposure of mice to vincristine and to a combination of X-rays and vincristine. *Reprod. Fertil. Dev.* 17(8):759-671.
- Dobrzyńska, M. M. 2003. The change in the quantity and in the quality to semen and sperm following sub chronic exposure of mice to chemotherapy: In Human Monitoring for Genetic effect. Edsm a, cebulska-wasilewaska, W. W. Au and R. J. Sram Clos. press: Amsterdam, the Netherlands. PP: 309-317.
- Egbelakin, A. 2011. Increased of Vinca alkaloids neurotoxicity associated with low CYP3A5 expression genotype in children with acute lymphoblastic leukemia. *pediatr. blood cancer*, 56: 361-367.
- Fairly, K. F., J. U. Barrie and W. Johnson. 1999. Sterility and testicular atrophy related to chemotherapy. *Lancet*, 1: 568.
- Galina, G. Hovhanisyan. 2010. Fluorescence insitu hybridization with comet assay and micronucleus. Test in genetic toxicology. *Molecular cytogenetics*, 3: 17, hovgalina@List.ru.
- Graf, W. D., P. F. Chance, M. W. Lensch, L. J. Eng, H. P. Lipe and T. D. Bird. 1996. Severe Vinca alkaloids neuropathy in Charcot-Marie-Tooth Disease type 1A. *Cancer*, 77(7): 1356-1362.
- Haskell, C. 1995. Antineoplastic Agents. In: Cancer Treatment. Philadelphia: W.B. Saunders Company.
- Al-Ahmed, Hazim I. A. 2010. Effect of some chemotherapy drugs vincristine and vinblastine on females albino mice fertility and sex hormones level.

- Journal of Biotechnology Research Center*. 4(2). Biotechnology Research Center/Al-Nahrain University.
- Hejazi, Sajjad and Jahangir-Fard Ramin. 2012. The Toxicity Study of Vinca alkaloids on Foeti of Pregnant Mice. 1Department of Basic Sciences, Tabriz Branch, Islamic Azad University, Tabriz, Iran 2Faculty of Veterinary Medicine, Tabriz Branch, Islamic Azad University, Tabriz, Iran. *Middle-East Journal of Scientific Research* 12(3): 322-324. ISSN 1990-9233.
- Joneja, M. and S. Ungthavorn. 1969. Teratogenic effects of Vinca alkaloids in three lines of mice. *Teratol.*, 2: 235-240.
- Karen, D., M. D. Wright, M. Daniel M. D. Green and Najat C. Daw, MD. 2009. Effects of Treatment for Wilms Tumor. *Pediatr Hematol Oncol*. 26(6): 407-413.
- Marvin L. Meistrich. 2013. Effects of chemotherapy and radiotherapy on spermatogenesis in humans. Department of Experimental Radiation Oncology, University of Texas M. D. Anderson Cancer Center, Houston, Texas. Electronic address: Fertility and sterility 09/2013; DOI: 10.1016/j.fertnstert. 2013.08.010 Source: PubMed.
- McEvoy, G., editor. 2004. American Hospital Formulary Service. Bethesda: American Society of Health-System Pharmacists.
- Meirow, D., H. Biederman, R. A. Anderson and W. H. Wallace. 2010. Toxicity of chemotherapy and radiation on female reproduction. *Clin Obstet Gynecol*. 53(4): 727-39.
- Perry, M. 2001. The Chemotherapy Source Book. Philadelphia: Lippincott Williams and Wilkins, p. 489-90.
- Roeser, H. P., A. E. Stocks and A. J. Smith. 1998. Testicular damage due to cytotoxic drug and recovery after cessation of therapy. *Aust. N. Z. J.* 8: 250.
- Said, R. A., L. F. Silva, A. R. O. L. Albuquerque, E. M. Sousa-Neta and M. O. Lavinsky. 2009. Efficacy and side effects of Vinca alkaloids treatment on Canine Transmissible Venereal Tumor-438. UESC/Hospital Veterinário, Rod. Ilhéus-Itabuna, Km 16, Salobrinho. Ilhéus/ BA, 45662-000, Brazil. E-mail: roueda@uol.com.br.
- Slaoui, M., and L. Fiette. 2011. Histopathology procedures: from tissue sampling to histopathological evaluation. *Histopathology Methods Mol. Biol.* 691: 69-82.
- Sadler, T. W. 2000. Longman's Medical Embryology. 9th ed., Lippincott, pp: 120-121.

- Sarah, C. P. and R. Williams Woods. 2012. Chemotherapy in parents may make offspring's DNA unstable and riddled with mutations. *Genetics: Searching for answers. Hum. Mol. Genet.* 21: 2399-2411.
- Wyrobek, J. Andrew, E. Thomas and F. M. Schmid. 2005. Cross-Species-Sperm-FISH. Assays paternal Risk for chromosomally abnormal pregnancies. *Environ. mol. Mutag.* 45: 271-283.
- Withrow, J. S. and E. G. Macewen. 2001. Transmissible Venereal Tumor, p.184, 533-537, 799-802, *In: Withrow J. S. and Vail D. (Ed.) Small Animal Clinical Oncology.* Philadelphia, WB Saunders.

دراسة جزيئية-نسيجية-مرضية في تأثير الفنبلاستين في دنا المبيض والخصى في الفئران البيضاء

رباب عبدالامير²

سعاد عبدالكريم محمد¹

منى ساجت هاشم^{4,1}

تغريد جبارحمادي¹

ذكري عبدالله محمود³

¹ قسم الأمراض، كلية الطب البيطري، جامعة بغداد، العراق

² قسم التشريخ، كلية الطب البيطري، جامعة ديالى، العراق.

³ قسم طب المجتمع، كلية الطب، جامعة الكوفة، العراق.

⁴ المسؤول عن النشر: sachitmuna@yahoo.com

المستخلص

صممت الدراسة الحالية لمعرفة تأثير الفنبلاستين في المبايض والخصى ومن ثم في عاقبة الأخصاب والحمل في الفئران البيضاء. استعمل خمسون (50) فأراً مختلطاً، (10) ذكور معاملة زوجت مع (10) إناث غير معاملة، و(10) ذكور غير معاملة زوجت مع (10) إناث معاملة وتركت (10) فئران مختلطة كسيطرة. أظهرت نتائج فحوصات الذكور هبوط في حساب النطف مع تشوهات شكلية في الخلايا المنوية. نتائج التقنية الجزيئية المطبقة على أنسجة الخصى والمبايض أظهرت بأن الإشارة الخضراء عبرت عن التلف الحاصل في الجين والإشارة الحمراء عبرت سلامة الجين والإشارة الصفراء عبرت عن تغير موقع الجين (الطفرة). أظهرت المشاهدات المرضية فقد تكوين النطف (انعدام النطف) مع تلف في أنسجة الخصى، وتليف المبيض مع تغيرات تنكسية في المبيض وحدث موت الجنين المبكر مع انعدام او قلة نسبة الأخصاب.

الكلمات المفتاحية: فنبلاستين، فأر، الحامض النووي، المبايض، الخصى.