

## GANGRENOUS MASTITIS IN LOCAL SHORT HAIRED FELINE

Karima A. Al-Salihi<sup>1,3</sup>      Ali Mosa Rashid Al-Yasari<sup>1</sup>      Hayder Ali Muhammad<sup>2</sup>

<sup>1,2</sup> College of Vet. Med., Al Muthanna and Karabala Universities respectively.

<sup>3</sup>Corresponding author: mrvsa59@gmail.com

### ABSTRACT

Feline mastitis is an uncommon inflammation of mammary gland. It is caused by bacterial infection of lactating gland, during pseudo pregnancy and galactostasis (accumulation of the milk). This study intends to describe a case of gangrenous mastitis in a queen and to isolate and identify the causative agent using PCR technique. Two-year-old, about 2.75- kg, female domestic shorthaired house cat was referred to the Veterinary Hospital, with the chief complaint of anorexia, lethargy and anxiety of 3 days duration with a noticeable decrease in body condition and a large open dark red wounds on her ventral caudal abdomen. A diagnosis of acute fulminant mastitis of the second- caudal left and right mammary gland with abscessation and gangrenous involvement swelling was made. Dark brown fluid were aseptically collected from the swollen glands and submitted to microbiological culture. Isolated microorganisms were identified based on macro and microscopical morphology by Gram stain, culture characteristics, biochemical profile and molecular techniques. *Staphylococcus aureus* and *E. coli* were identified as the causative agents. *E. coli* pathogenicity was approved by confirmation of CS1 expression gene by molecular technique. The cat was successfully treated with systematic antibiotics and open wound management using surgical debridement and lavage followed by wound dressings using local antibiotic. In conclusions, this case report highlights the gangrenous mastitis and its causative agents in feline, in addition to its respond to the medical treatment procedures. So far as we are aware, and for the authors knowledge, this is the first report regarding gangrenous mastitis in Iraq.

**Key words:** *E. coli*, feline, gangrenous mastitis, nipple, pcr, SC1.

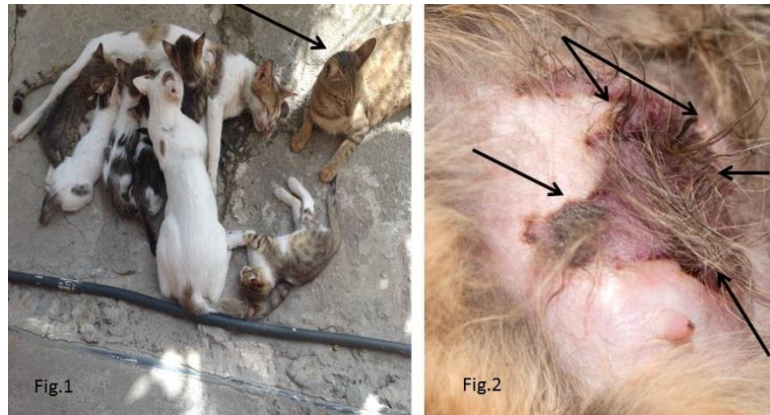### INTRODUCTION

The cats have four pairs of teats, two thoracic and two abdominal, which are about equidistantly spaced. The supernumerary teats do also occur in cats. The number of ducts opening on a teat varies from 1 to 7 external openings per teat for the cat and are situated on the blunt end of the teat in an irregular shape. Each milk exit can be an entry point for bacteria (Barone, 1996). The queen has a big tasks including the carrying of the kittens to term and nursing them once

born. Through this time, their mammary glands are stimulated to produce milk. The stress of pregnancy, nursing, and sharp kitten teeth generate a suitable environment for bacteria. In all cases, the nursing cat's immune system can resist the bacteria, but if queen lacks proper nutrition, is overly stressed, or is struggling with other factors, her immune system can't successfully clear the bacteria and an infection develops. Mastitis is most common in older cats. It is an inflammation of the mammary glands that is varied in the number of affected glands from case to case. It is a more common problem during the postpartum period in lactating gland, during pseudo pregnancy and a galactostasis that occurred due to accumulation of the milk in the gland (Burstyn, 2010). The lack of hygiene, an abrupt weaning, suction of the kittens themselves and death of a kitten are among the factors which may predispose the onset of mastitis. Mastitis is more than simple inflammation, and can also entail an infection. *E. coli*, *Staphylococci*, *streptococci* and *enterococci* are the most common bacteria that cause mastitis of the cat (Demirel and Ergin, 2014). The infection always starts at the nipple and rises to the mammary glands. Feline mastitis can range from mild inflammation that barely presents any symptoms to severe infection with gangrene, that is, the death of the tissue due to lack of blood supply. The researcher are believed that the microorganisms gain entrance via fissures in the nipples and adjacent skin or spread by way of both the ducts and the lymphatics (Demirel and Ergin, 2014). *Staphylococcus spp.*, *Streptococcus spp.* and *Coliforms*, are the most commonly isolated causative organisms from feline mastitis. Gangrenous lesions can be occur within a few days by the persistent pathogenic *staphylococci spp.* Review of literature revealed scarce publication on feline mastitis in general and gangrenous mastitis in specific worldwide. Moreover, for the authors knowledge, no publication were published on feline gangrenous mastitis in Iraq. Therefore, this study intends to describe a case of gangrenous mastitis in a queen and its response to the treatment, moreover, to isolate and identify the causative agent using PCR technique.

### CASE PRESENTATION

Two-years-old, about 2.75- kg, female domestic shorthaired house cat was referred to the Veterinary Hospital, with the chief complaint of anorexia, lethargy and anxiety of 3 days duration (Figure 1) with a noticeable decrease in body condition and a large open dark red wounds on her ventral caudal abdomen (Figure 2).



**Figure 1. Shows the sick queen that neglected her kitten**

**Figure 2. Shows the lesion of gangrenous mastitis in the queen**

The cat was refrained to nurse her kitten and segregate from them. A diagnosis of acute fulminant mastitis of the second- caudal left and right mammary gland with abscessation and gangrenous involvement swelling, was made. Dark brown fluid were aseptically collected from the swollen glands and submitted to microbiological laboratory. The samples were culture on sheep blood agar (5%), MacConkey agar and incubated under aerobic and anaerobic conditions. The isolated microorganisms were identified based on macro and microscopic morphology, Gram stain, culture characteristics, biochemical profile and molecular techniques. The culture samples generated a hemolytic *E. coli* and *Staphylococcus aureus*. Both microorganisms were purified and identified according to methods previously reported by Carter (1990) and Carter *et al.*, (1995). DNA was extracted from isolated *E. coli*. The *E. coli* were grown in Brain Heart Infusion broth with shaking, after overnight incubation at 37 °C. The culture centrifuged at 12.000 g for 2 minutes. The bacterial pellets collected and re-suspended in 500 ml in 0.85% Sodium Chloride and incubated with Tris-HCl (40 mmol l<sup>-1</sup>), EDTA (20 mmol l<sup>-1</sup>) and SDS (0.8%) at 37 °C for 1 hour. The bacterial DNA lysates was purified with an equal volume of phenol and chloroform mixture (1:1). The aqueous phase was collected and the extraction repeated. Later on, DNA precipitated using 95% alcohol. After centrifugation at 12.000 g for 2 min, DNA pellets were dried and re-suspended in Tris-EDTA buffer (10 mmol l<sup>-1</sup> Tris-Cl and 1 mmol l<sup>-1</sup> EDTA, pH 8.0). CS1 gene was detected in *E. coli* in this study. The PCR primers were designed. The nucleotide sequences of the primers are as following:

Forward primer: TCCGTTTCGGCTAAGTCAGTT

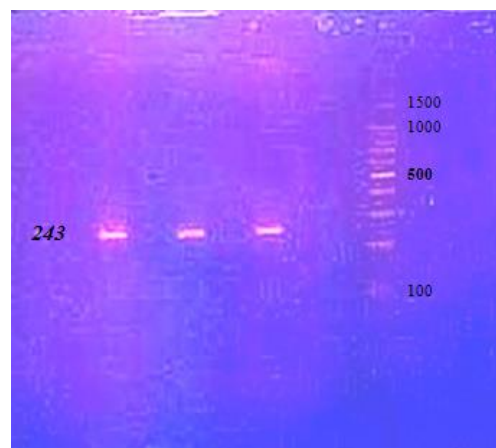
Reverse primer: CCGCACATTTCTGTGTTCT

The DNA templates were amplified and electrophoresed on 1% agarose in 1X TBE buffer (0.089 mol l<sup>-1</sup> Tris-borate, 0.089 mol l<sup>-1</sup> boric acid and 0.002 mol l<sup>-1</sup> EDTA; pH 8.0). The bands were photographed using a digital camera.

The cat was treated after sample collection. The affected area was washed with sterile saline solution (0.9% NaCl) and local antibiotic infiltration was also injected. Later on, affected area was washed with Povidone-iodine. Systemic antibiotic (the combination of amoxicillin and clavulanic acid (8.75 mg kg<sup>-1</sup> day<sup>-1</sup>, IM) was injected intramuscularly for 5 days. After 6 days the cat was re-evaluated clinically. She was bright, attentive and reactive, moreover, all her vital parameters were within normal limits. The wound was revealed a layer of granulation tissue and no purulent or pus/necrotic debris was free of. The affected area was smaller in diameter, measuring 4-5 cm wide.

## RESULTS

Golden–yellowish, circular, beta–hemolytic colonies associated to grayish, non–hemolytic colonies were obtained after 24 h on sheep blood agar, while on MacConkey agar, pink colonies (lactose–positive) were observed in pure cultures after 24 hrs. *S. aureus* and *E. coli* were identified as the causative agent according to biochemical tests. The results of molecular detection of the isolated *E. coli* was positive for CS1 gene. The gel picture in figure 3 shows the amplification results of the *E. coli*.



**Figure 3. Shows the expected bands in the isolated *E. coli***

## DISCUSSION

Feline mastitis is not well assumed. Clinical, bacteriological, cytological, hematological, and pathological analyses were described previously and approved that mastitis may lead to subclinical disease and that presence of bacteria and leukocyte increases are the main features of mastitis in bitches and queens. In contrast to ruminant mastitis, increased leukocytes are present in adjacent mammary glands and not only in the individually affected ones

(Ververidis *et al.*, 2007). To the authors knowledge, this is the first description of gangrenous mastitis in a cat. The diagnosis was based on history, clinical signs, and physical findings in this nursing lactating female. The more common clinical signs of mastitis are swollen, firm or ulcerative mammary gland tissue and glandular discharge, pain, increased body temperature, anorexia, vomiting, exhaustion, depression and reluctance to care for her kitten (Davidson, 2008 ; Johnston *et al.*, 2001 ; Laliberté, 1986 ; Wiebe and Howard, 2009). In this report, the queen with acute gangrenous mastitis revealed mild dehydrated, increased in body temperature and mammary glands were hot, swollen, painful, with necrosis, abscessation and purulent discharge in one affected teat. Besides, the queen prevented their offspring to suckling and another nursing cat accepted this task. The treatment regime used in this case was effective and the queen was recovered after a combination of systematic and local treatment. This observations is compatible with previous report (Gruffydd-Jones, 1980). Culturing and identification should be done on milk, fluid from the incised abscess, and from necrotic tissue on every occasion possible (Traas and O'Connor, 2009). *Escherichia coli* is the most causative agent, though *Staphylococcus spp.*, *Streptococcus spp.*, *Enterobacter spp.* have also been isolated (Davidson, 2008 ; Johnston *et al.*, 2001). Moreover, the predisposing factors must usually be found for disease development (Graham and Taylor, 2012). The origin of infection in this case was not identified, however, ascending infection via nursing or mammary gland trauma was highly suspected. *Escherichia coli* and *Staphylococcus aureus* were isolated and identified from this queen. This results are in agreement with observation of previous reports (Gruffydd-Jones, 1980). *Escherichia coli*, is a Gram- negative facultative anaerobe, and it is a normal part of the gastrointestinal microflora in mammals (Graham and Taylor, 2012). Endotoxins released from the *E. coli* cell wall can reach the systemic circulation and activate the host systemic inflammatory response. The physiological and metabolic stress after parturition that lactating queen went through, in a combination with *E. coli* endotoxin and systemic inflammatory response led to express the systemic clinical signs in the current case. If the queen left without treatment, uncontrolled response may occurred and cause multi-organ failure due a fatal potential outcome of *E. coli* endotoxemia. These observations are in agreement with previous observations reported previously (Graham and Taylor, 2012). In this case, *E. coli* was isolated from affected mammary glands and identified according to morphological and biochemical criteria that revealed typical characteristic features for *E. coli*.

These results are compatible with previous reports (Wilson, 2013). In this study, CS1 expression gene was detected in the isolated *E. coli* using molecular technique. This result is compatible with previous results reported by Caron *et al.*, (1989). The isolated *E. coli* to be virulent must produce a toxin and pilus-like structure necessary in attachment to host tissue that requires the presence of plasmid in an ETEC strain of a particular serotypes and biotype. Clinical isolates of some *E. coli* strains contain large plasmids ranging in size from 32 to 115 MDa that are highly evolved for virulence (Smith *et al.*, 1986 ; Boylan and Smyth, 1985 ; Echeverria *et al.*, 1986). These plasmids, required for expression of the colonization factors CS1 and CS2 in appropriate hosts that approved in the current study (Caron *et al.*, 1989). *Staphylococcus aureus* was also isolated in this study. It is a member of the normal microflora inhabiting feline skin. The stressful predisposing factors enables *Staphylococcus aureus* opportunistic infection of the mammary gland that might cause gangrene within few days (Gruffydd-Jones, 1980). In Conclusions, this study highlighted a case report of gangrenous mastitis in queen, additionally, its causative agents were confirmed. The queen showed excellent response to the medical treatment procedure. *E. coli* and *Staphylococcus aureus* was isolated from this case. *E. coli* pathogenicity was approved by the confirmation of CS1 expression gene by molecular technique.

## REFERENCES

- Barone, R. 1996. Anatomie compare´e des Mammife`res domestiques. Tome 5: Angiologie. Paris: Vigot.
- Boylan, M. and C. J. Smyth. 1985. FEMS Microbiol. *Lett.* 29: 83-89.
- Burstyn, U. 2010. Management of mastitis and abscessation of mammary glands secondary to fi broadematous hyperplasia in a primiparturient cat. *Journal of the American Veterinary Medical Association.* 236(3): 326-329.
- Carter, G. R. 1990. Isolation and identification of bacteria from clinical specimens. *In:* Carter GR, Cole JR. (Eds.). Diagnostic Procedures in Veterinary Bacteriology and Mycology. 5th edition, Academic Press Inc. San Diego, California.
- Carter, G. R., M. M. Chengappa and A. W. Roberts. 1995. Essentials of Veterinary Microbiology, 5th edition, Williams and Wilkins, Baltimore, Philadelphia.
- Courtney, R. Wilson. 2013. Feline gangrenous mastitis. *Canadian Veterinary Journal,* 54: 292-294.

- Davidson, A. 2008. Mastitis. Standards of care: *Emergency and critical care medicine*. 10(1): 61-67.
- Demirel, M. A. and I. Ergin. 2014. Approach to gangrenous mastitis related to galactostasis in a cat. Medical and surgical. *Acta Scientiae Veterinariae*. 42(Suppl 1): 50.
- Echeverria, P., J. Seriwatana, D. N. Taylor, C. J. Changchawalit Smyth, J. Twohig and B. Rowe. 1986. Plasmids coding for colonization factor antigens I and II, heat-labile enterotoxin, and heat-stable enterotoxin A2 in *Escherichia coli*. *Infection and Immunity*, 51(2), 626-630. 51: 626-630.
- Graham, E. M. and D. J. Taylor. 2012. Bacterial reproductive pathogens of cats and dogs. *Vet. Clin Small Anim.*, 42: 561-582.
- Gruffydd-Jones, T. J. 1980. Acute mastitis in a cat. *Feline Practice*. 10(6): 41-42.
- Johnston, S. D., M. V. Root Kustritz and P. N. S. Olson. 2001. The postpartum period in the cat. *In: Johnston S. D. and Root M. V. Canine and Feline Theriogenology*. Philadelphia, PA, Saunders. Pp.413-424.
- Judy Caron, Lisa M. Coffield and June R. Scott. 1989. A plasmid-encoded regulatory gene, rns, required for expression of the CS1 and CS2 adhesions of enterotoxigenic *Escherichia coli*. *Proc. Natl. Acad. Sci. USA*, 86: 963-967.
- Kustritz, M. V. and P. N. S. Olson (Eds.). *Canine and Feline Theriogenology*. Philadelphia: Saunders Company. 438-446.
- Laliberté, L. 1986. Pregnancy, obstetrics and postpartum management of the queen. *In: Morrow D. A. (Ed). Current Therapy in Theriogenology*. Philadelphia: W.B. Saunders Company, Pp. 812-821.
- Smith, H. R., S. M. Scotland and B. Rowe. 1983. Plasmids that code for production of colonization factor antigen II and enterotoxin production in strains of *Escherichia coli*. *Infection and Immunity*. 40(3): 1236-1239.
- Traas, A. M., C. O'Connor. 2009. Postpartum emergencies. International Veterinary Emergency and Critical Care Symposium.
- Ververidis, H. N., V. S. Mavrogianni, I. A. Fragkou, D.C. Orfanou , Gougoulis D. A. Tzivara, P. G. Gouletsou, L. Athanasiou, C. M. Boscog, G. C. Fthenakis. 2007. Experimental staphylococcal mastitis in bitches: Clinical, bacteriological, cytological, haematological and pathological features. *Vet. Microbiol.*, 124: 95-106.
- Wiebe, V. J. and J. P. Howard. 2009. Pharmacologic advances in canine and feline reproduction. *Topics in Companion Animal Medicine*. 24(2): 71-99.

## التهاب الضرع المواتي (الغنغرينيا) في القط المحلية ذات الشعر القصير

حيدر علي محمد<sup>2</sup>

علي موسى الياسري<sup>1</sup>

كريمة عاكول الصالحي<sup>3,1</sup>

<sup>2,1</sup> كلية الطب البيطري، جامعة المثنى وجامعة كربلاء على التوالي، العراق.

<sup>3</sup>المسؤول عن النشر: mrvsa59@gmail.com

### المستخلص

التهاب الغدد اللبنية غير شائع الحدوث في القطط، لذا هدفت هذه الدراسة الى وصف التهاب الضرع المواتي (الغنغرينيا) في انثى القط المحلية (الملكة) وكذلك عزل وتوصيف المسببات المرضية باستخدام تقنية سلاسل تفاعل البلمرة PCR.

تم استقبال قطة تعاني من فقدان الشهية والقلق والعزلة لمدة ثلاثة ايام مع وجود جرح كبير مفتوح، واحمرار في الجانب البطني الخلفي. شخّصت الحالة بأنها التهاب الضرع الحاد الشديد مع الغنغرينيا. عزلت الجراثيم من الافرازات البنية الغامقة للضرع الملتهب المتضخم، وشخّصت المكورات العنقودية الذهبية والايشريشيا القولونية كمسببات مرضية لهذه الحالة. حددت امراضية الايشيريشيا القولونية بالكشف عن جين CSI باستخدام تقنية الـ PCR. وتم معالجة هذه الحالة بنجاح باستخدام المضادات الحيوية الجهازية والموضعية مع علاج موضعي للجرح. في الخلاصة، القت هذه الدراسة الضوء على التهاب الضرع الغنغريني في القطة. ولعلم الباحثين هذه الدراسة هي الاولى التي سجلت التهاب الضرع الغنغريني بالقطط في العراق.

الكلمات المفتاحية: الأشريشيا القولونية، القطط، التهاب الضرع الغنغريني، الحلمة، PCR، SCI.